

# Using the Fractal Dimension to Evaluate the Alveolar Bone Growth after Implant Placement in Alveolar Bone- A Case Report

Huang Chih-Chia\*, Chen Chien-Chih, Chen Jing-Huey, Tai Yuen-Sheng, Lai Tat-Ming,  
Dental Department of Cardinal Tien Hospital

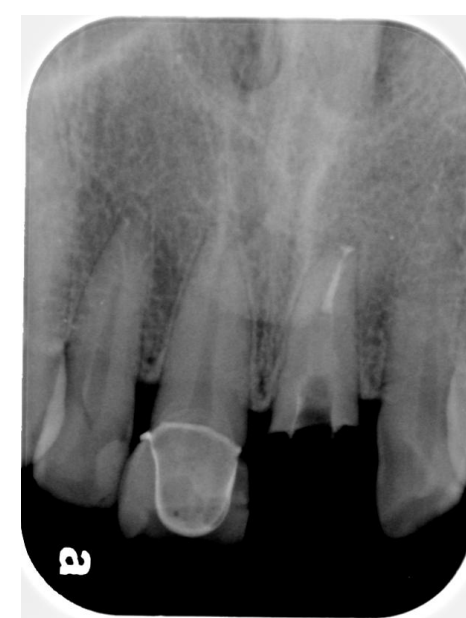Mr. Huang Chih-Chia, 362, Chung Cheng Rd., Hsinten, New Taipei City 23137 Taiwan R.O.C  
886-2-89115401, 886-920040347, Email: frank554@ms13.hinet.net

## Abstract

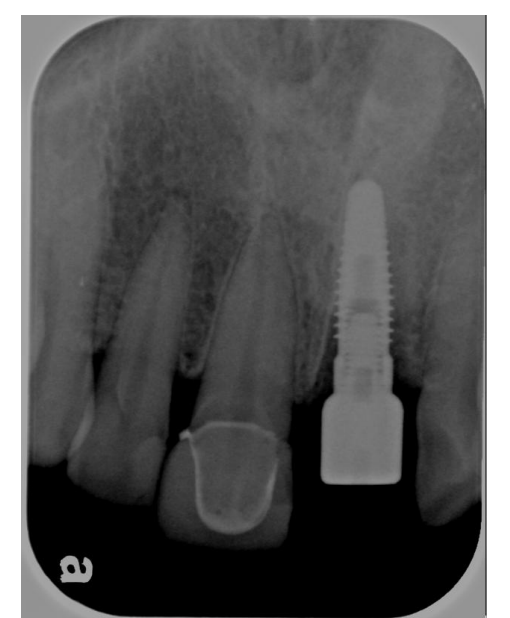The time for estimate the stability of the new bone connected implant were base on the radiography image comparison and sonic test and experience. The FD (Fractal Dimension) method not only used in bone density and quality evaluation alveolar bone healing after endodontic surgery, but also to evaluate the bone healing after alveolar bone surgery . The case report was a 38 years old male suffered upper left central incisor (21) crown and root fracture. He accepted the treatment 21 extraction and 4.3 diameter 11mm Camlog implant placement immediately. Then we used the FD method to test alveolar bone on the radiography image from, 1month, 4months, 5months 6months and 10 months. This case showed that the FD method may use to estimate the new bone growth in the immediate implant placement

## Case Report

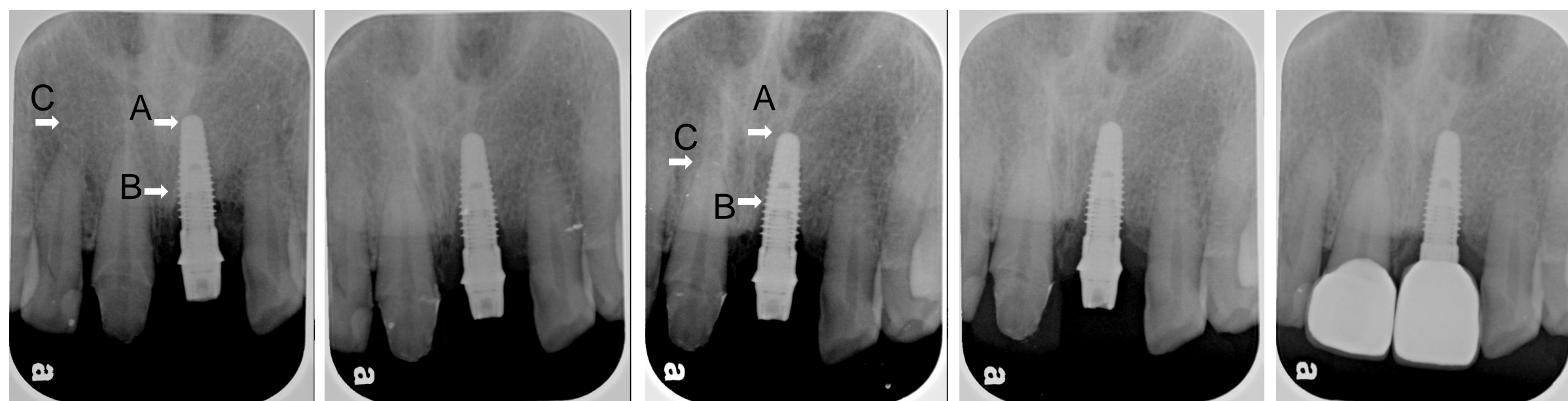The patient asked the treatment for the upper left central incisor(21) crown root fracture to our dental department of the Cardian Tien Hsopital. In the clinical finding, the incisor residual root less than ten meter and mild PDL widening from the root apex radiography image. The PMH is normal and PDH had OD, ENDO and single crown restoration. The diagnosis for the patient's 21 was residual root and chronic apical periodontitis. The treatment plan for the 21 was extraction, then single implant restoration immediately.



Initial Radiography



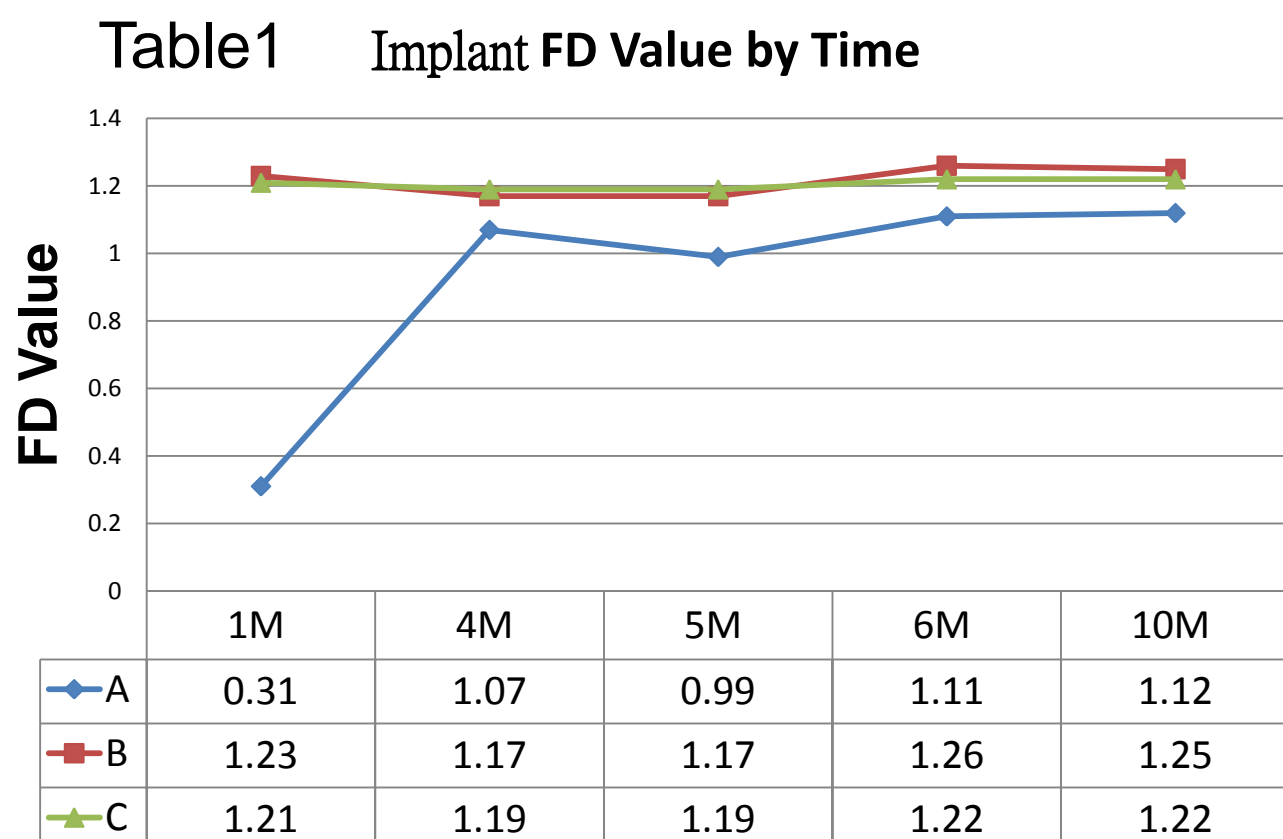
Camlog implant 4.3mm, 11mm diameter placement



We test the region of interesting (ROI) in the 21 implant apex and mesial side of the bone(5<sup>th</sup> screw) and 12 healthy bone. The result showed that the FD value change (Table1).

A= 21 Implant Apex  
B= 21 Implant at 5<sup>th</sup> Screw ( from coronal to apex )  
C= 12 Root Apex

Figure 1 The radiography image of implant from implant placement to the ten months  
1Month 4Months 5Months 6Months 10Months



## Result

The case report showed that the FD method may used to test the bone growth of implant placement to help evaluate the new bone growth.

