

Digital Approach to Maxillary Lateral Incisor Replacement: Planning

Ceccacci LM, Bergler S, Flaherty P, Hunt PR: Philadelphia, PA, USA

Laura M Ceccacci: Laura@camlogconnect.com

Introduction

Recent advances in diagnostic and planning capabilities for guided implant placement have allowed for an increasingly faster, simpler and easier workflow. Using new technology, the dental team is able to virtually design and produce surgical guides within the office. This can be achieved using a CBCT scan, an intraoral scan, surgical guide planning software, and a 3D printer. After the surgical guide is manufactured, the guide can be used to help construct abutments and provisional restorations prior to the surgical appointment.

Clinical Situation

An aesthetically conscious patient presented with congenitally missing lateral incisors. She had been wearing Maryland bridge restorations for more than 20 years and was dissatisfied with their appearance. Periapical radiographs showed that the adjacent teeth were extremely close. Since the patient had very limited available space for dental implants, a digital work-up for the case was indicated to ensure greater precision.

Design and Planning

To help treatment plan the case, the patient had a CBCT scan (Sirona Galileos) and a full maxillary arch intraoral scan (3Shape TRIOS). Implant size and positioning had been virtually planned by the clinician in the Galileos software. It quickly became obvious that in addition to issues of potentially impinging on adjacent teeth, there was very little labio-to-lingual dimension to the alveolus. This meant that it would be relatively simple to unintentionally perforate outside of the alveolus while drilling the implant channel. Since there was limited available space, it was determined that a Surgical Guide was needed to increase the safety, speed and precision of the implant placement. In addition, using the surgical guide, restorative work could be planned and prepared in advance. This would be available to be placed after the surgery or during the healing period.

Procedure

After determining a surgical guide was required for implant placement, we moved to Implant Studio (3Shape) for the design of the surgical guide. First, the .STL file from the intraoral scan and the DICOM dataset from the Galileos CBCT scan were both uploaded into Implant Studio. The intraoral scan and DICOM dataset were then merged using a three-point alignment. Then it was then possible to plan and generate the proposed positioning of the implant channels.

Procedure (continued)

The need for precision was to ensure that the implants would be placed within bone, without contacting the adjacent teeth, and emerging from the soft tissue complex in a suitable position for restoration. Once the implant positions satisfied the aesthetic demands and spatial requirements of the case, the surgical guide was virtually designed, which would ensure the precise placement of the implants in the proposed positions. An .STL file of the surgical guide was then generated from Implant Studio. This was exported to an outside laboratory for 3D printing (Core3D, Las Vegas, NV). The surgical guide allowed us to produce a master model with implant analogs in the positions proposed for the implants. This allowed bonded temporary bridges and initial abutments and temporary crowns to be created.

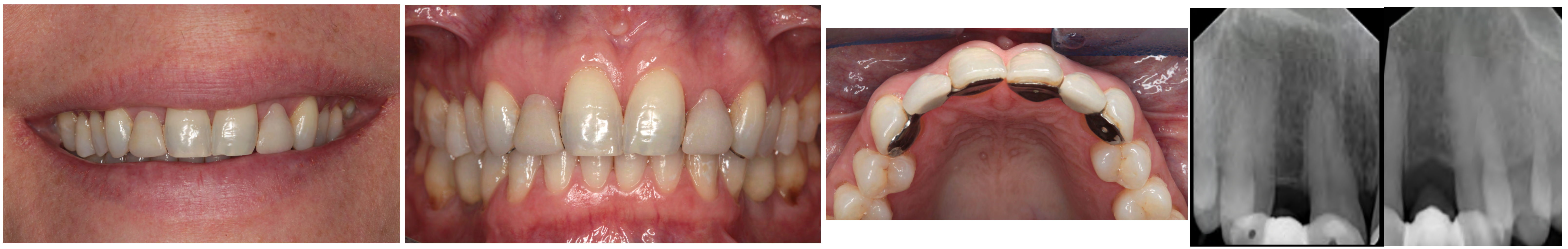Discussion

This work flow helps make the surgical and restorative procedures go much more smoothly and predictably. It cuts down on clinical time, increases productivity and because of this, reduces costs. The use of intraoral scans, a surgical guide, and digital technology greatly increases the precision of implant placement.

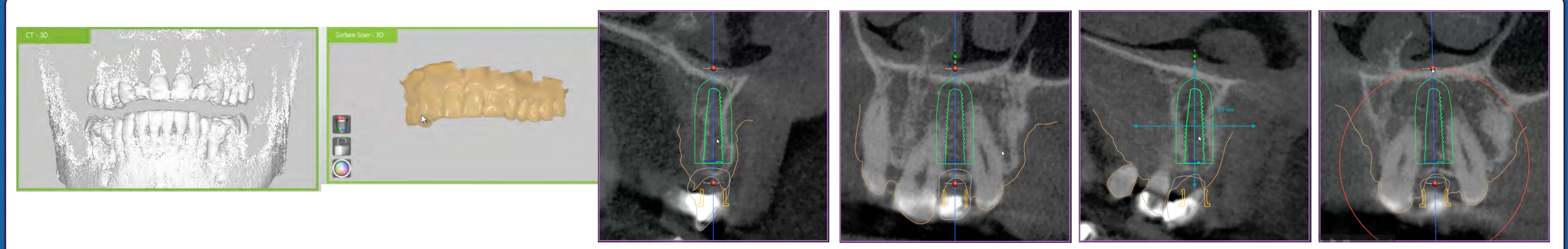
Having the bonded temporary bridges and initial abutments and temporary crowns ready facilitated therapy so they were available to be placed at the time of the procedure or shortly thereafter. In this case that was when the implants were osseointegrated.

Conclusions

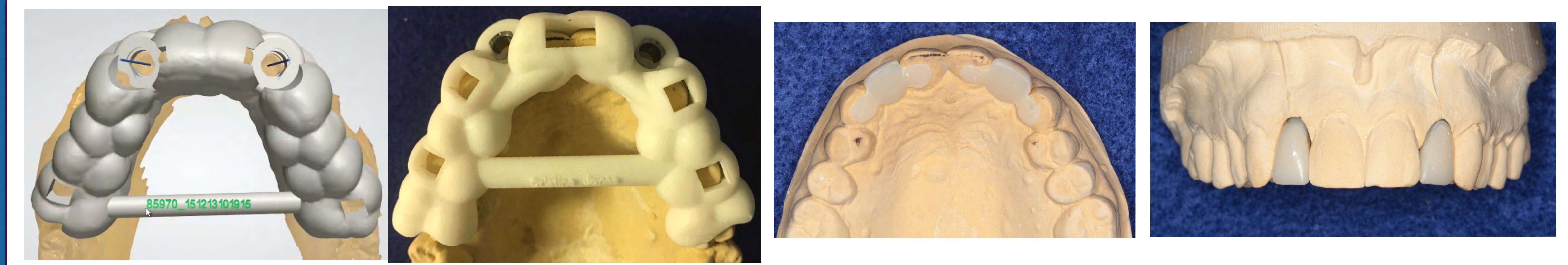
Conventional freehand implant placement in this case could easily cause considerable damage to the alveolus and the adjacent teeth. The surgical guide allows for increased safety, enhanced precision and speeds up implant placement. The implant planning, surgical guide, and temporary restorations can all be developed in-house prior to the implant procedure. This saves considerable development time. The Surgical Guide design process takes less than an hour. At the implant procedure, placement can go very smoothly and efficiently. Having the restorative components at hand, the clinician has the opportunity to work with two different restorative options. Overall the process has great benefits and savings for both clinician and patient.



A 45-year-old female presented with congenital anodontia of the maxillary lateral incisors. She disliked the feel and appearance of the Maryland Bridge that she had been wearing for more than 20 years. She requested implant-supported restorations.



A DICOM file from a CBCT Scan was merged with an .STL file from an intra-oral scan. It was then possible to virtually plan the size and position of implants and from that to propose a Surgical Guide for implant placement. This was produced by 3D printing.



The proposed virtual design of the Surgical Guide.

The 3D printed Surgical Guide with Camlog® Surgical Guide rings in place.

Working model with adhesive temporary bridges prepared for clinician.

Working model with temporary abutments and crowns.