

# Effect Of Dental Implants On Bisphosphonate-Related Osteonecrosis Of The Jaws

<sup>1</sup>DANIEL HOLZINGER MD, DMD; <sup>1</sup>RUDOLF SEEMANN MD, DMD, PhD; <sup>1</sup>NADJA MATONI DMD; <sup>1</sup>ROLF EWERS MD, DMD, PhD;  
<sup>2</sup>WERNER MILLESI MD, DMD, PhD; <sup>1</sup>ARNO WUTZL MD, DMD, PhD

<sup>1</sup> University Clinic of Craniofacial, Maxillofacial and Oral Surgery, Medical University of Vienna, Austria

<sup>2</sup>Institute of Oral and Maxillofacial Surgery and Dentistry, Krankenhaus Hietzing, Wolkersbergenstrasse1, 1130 Vienna, Austria

## Purpose:

In the present study we analyze the time span of developing BRONJ in patients treated with bisphosphonates and receiving dental implants.

## Study design:

In this metaanalysis patients with dental implants and established BRONJ were evaluated at

the department of oral and maxillofacial surgery, Medical University of Vienna. In

Addition 11 studies from 1978 to 2012 were included in a meta-analysis. Three groups

were created:

a) implantation before bisphosphonate treatment,

b) implantation after bisphosphonate treatment,

c) implantation during bisphosphonate treatment. Outcomes

were evaluated by linear regression analysis.

## Results:

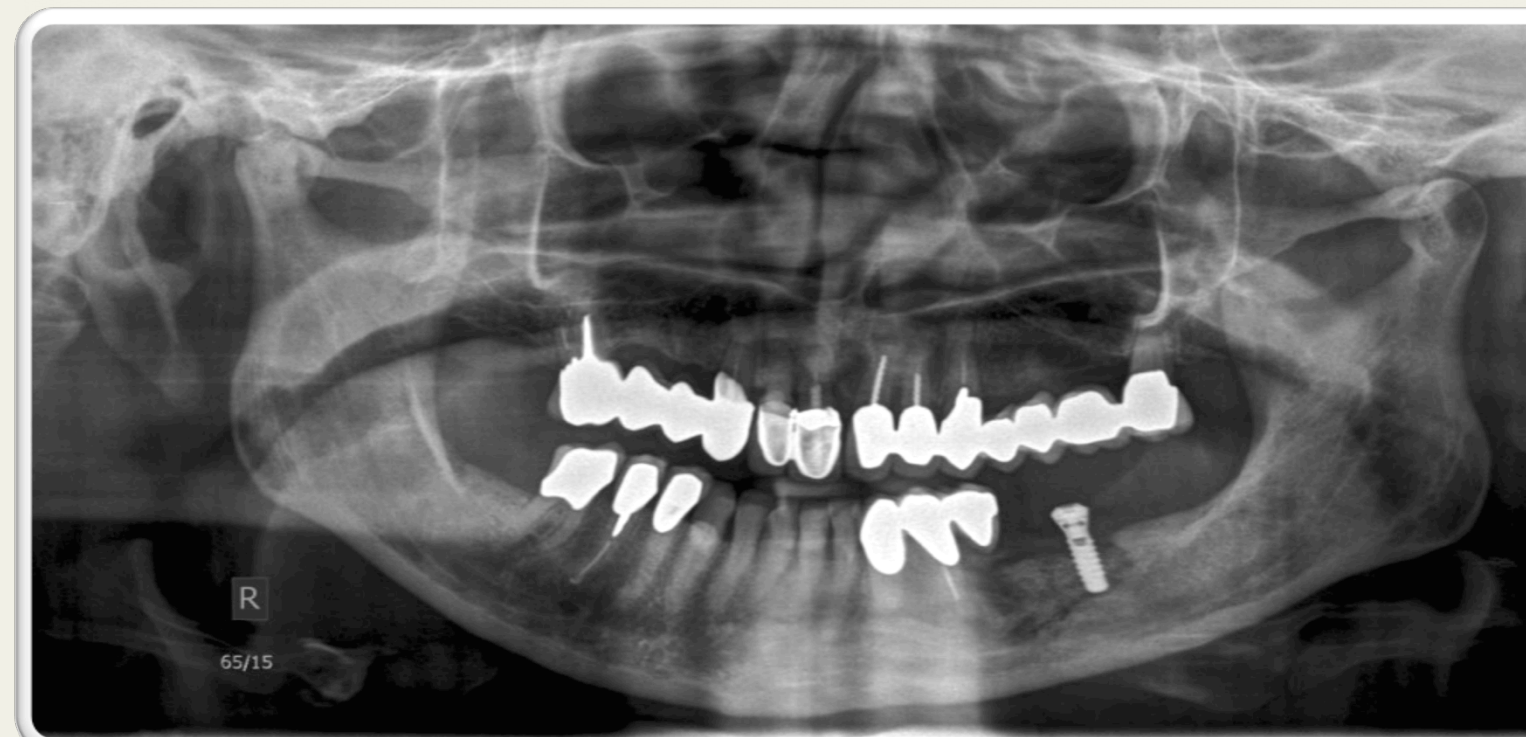Patients who underwent dental implantation during ( $p < 0.001$ ) and after ( $p < 0.001$ ) treatment with bisphosphonates developed BRONJ more rapidly. The duration of treatment with oral bisphosphonates was significantly related to the rapidity of developing BRONJ ( $p = 0.03$ ).

## Conclusion:

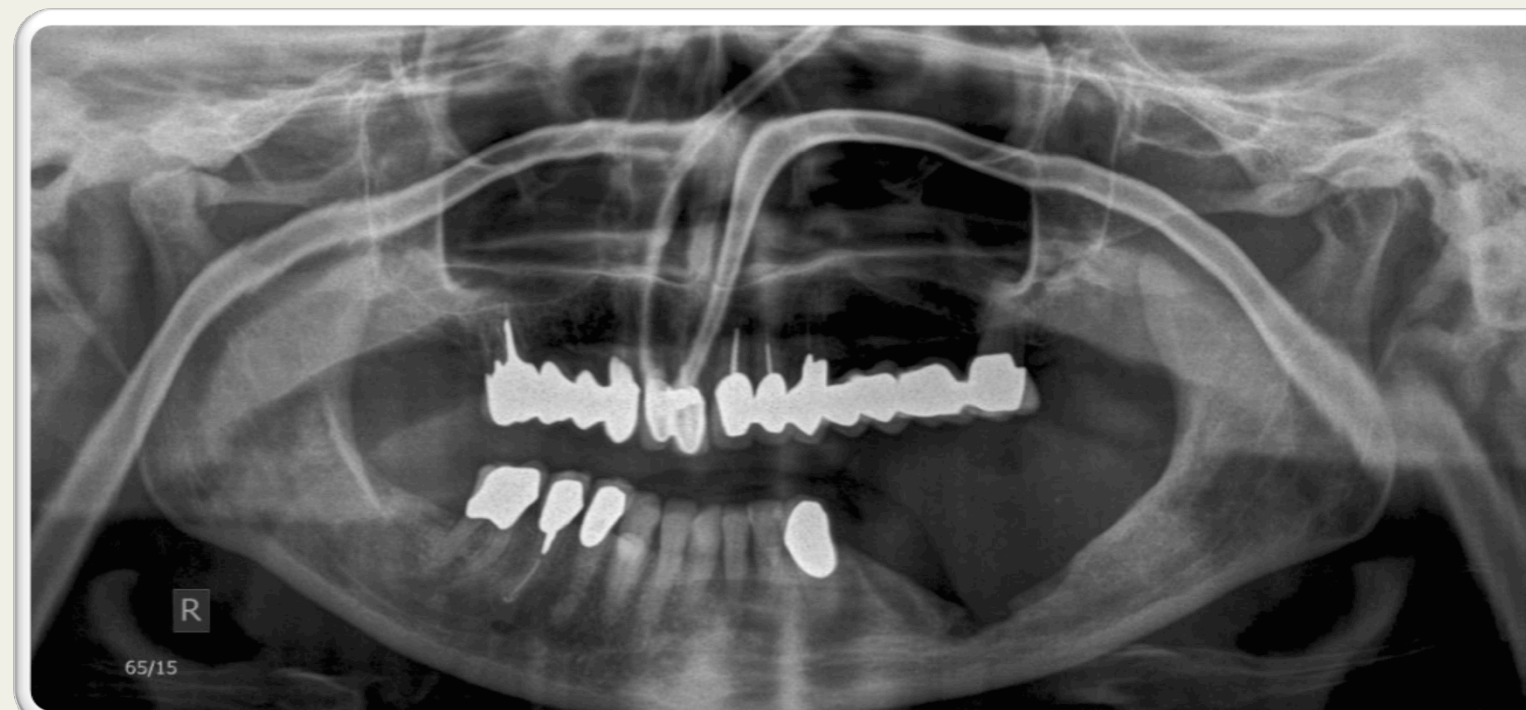The insertion of dental implants during or after bisphosphonate treatment accelerates the development of BRONJ. BRONJ occurred less frequently when implants had been inserted before bisphosphonate therapy started.

Implants	Total (n=)	Median (n=)
Inserted	47	4
Last follow up	17	0

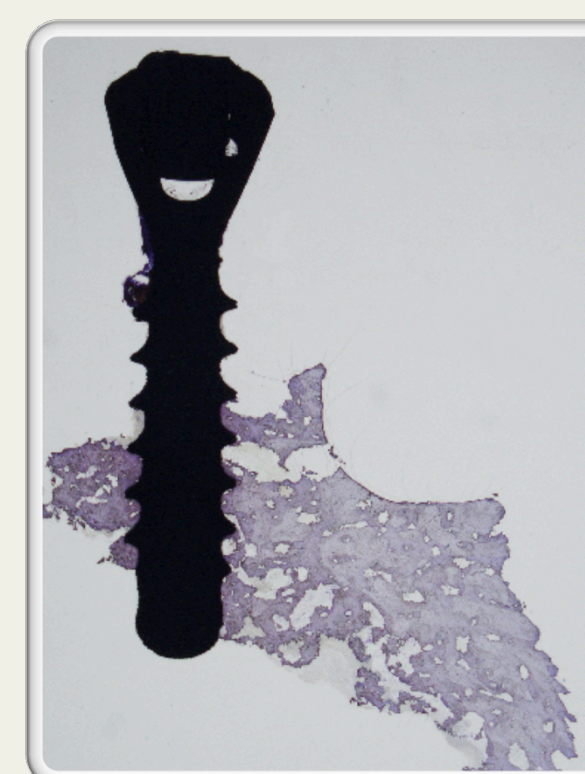Original number (n) of inserted implants versus number of dental implants at the last follow-up investigation



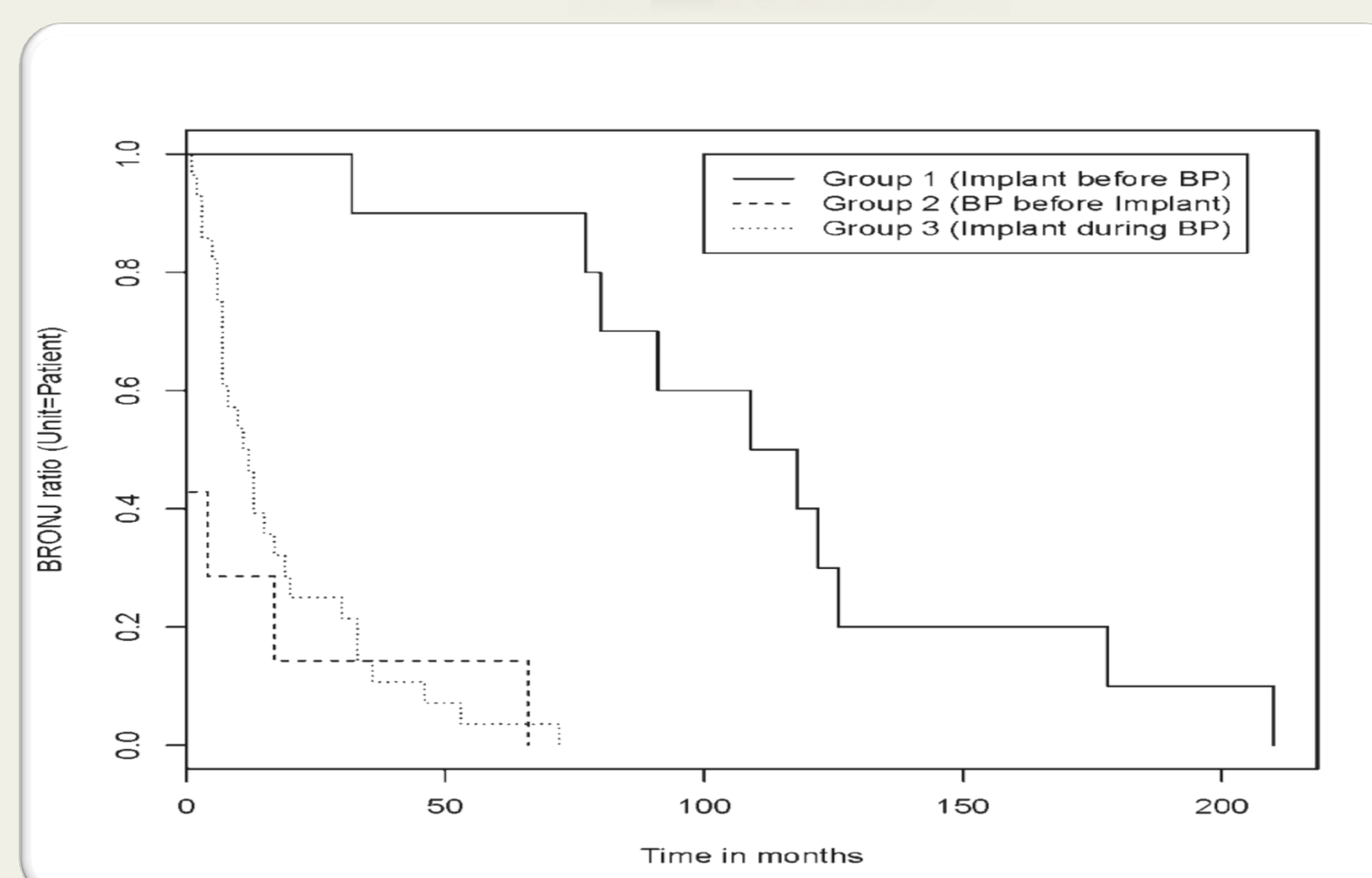
Radiograph of BRONJ affecting osseointegrated implant



Radiograph after removal of osteonecrotic bone and dental implant



Histological section of osseointegrated implant after removal of necrotic bone shown above



Kaplan-Meier curve DI to BRONJ in months with reference to the number of patients. The figure encompasses all studies included in the analysis (n=54).

Financial support for research and medical editorial assistance was provided by a CAMLOG Foundation Grant CF 41105

All authors declare that there are no commercial associations, current or in the past five years, that might pose a potential, perceived, or actual conflict of interest.

**Reference:** Effect of dental implants on bisphosphonate-related osteonecrosis of the jaws

Daniel Holzinger; Rudolf Seemann; Nadja Matoni; Rolf Ewers; Werner Millesi; Arno Wutzl DOI: 10.1016/j.joms.2014.04.037 In Press, Accepted Manuscript, May, 26, 2014

**Contact:** DANIEL HOLZINGER, University Clinic of Craniofacial, Maxillofacial and Oral Surgery, Medical University of Vienna, Austria, Waehringer Guertel 18-20, A-1090 Vienna  
Tel: +43 1 40400 4252, Fax: +43 1 40400 4253, [daniel.holzinger@meduniwien.ac.at](mailto:daniel.holzinger@meduniwien.ac.at)



