



Comparison between panorama and CBCT reformatted panoramic images for presurgical dental implant assessment



Jae-Yeol Lee¹, Yong-Deok Kim¹, Cheol hong Kim²

¹Dept. of Oral and Maxillofacial Surgery, School of Dentistry, Pusan National University

²Dept. of Dental Anesthesia and pain Medicine, School of Dentistry, Pusan National University

INTRODUCTION

For implant planning, clinical evaluation, model study, radiographic exams are necessary. Through the radiographic exams, alveolar bone and basal bone quantity and quality could be evaluated. It is very important to determine the location and length of the implant.

Panorama is simple and it shows the maxilla and mandibular anatomical structures at a glance. However, the image is different from the anterior and posterior / horizontal and vertical magnification. CBCT is accurate and there is no overlap of the surrounding tissue. However, the relatively long exposure time can cause errors due to patient motion.

Two different imaging modalities used for pre-implant assessment were compared in this study: panorama and CBCT reformatted panoramic images. The CBCT data were reformatted to one panoramic image per patient. Distance from the maxillary sinus and inferior alveolar nerve to alveolar crest were compared.

MATERIALS & METHODS

1. Subjects

- (1) Patients who need implant surgery at PNUDH from June 2014 to Feb 2015
- (2) Sample comprised 22 patients, 42 implant sites, premolar and molar regions

2. Digital panoramic images

- Panoramic images using the **Marosis m-view** version 5.4 program (Infinite, Seoul, Korea)

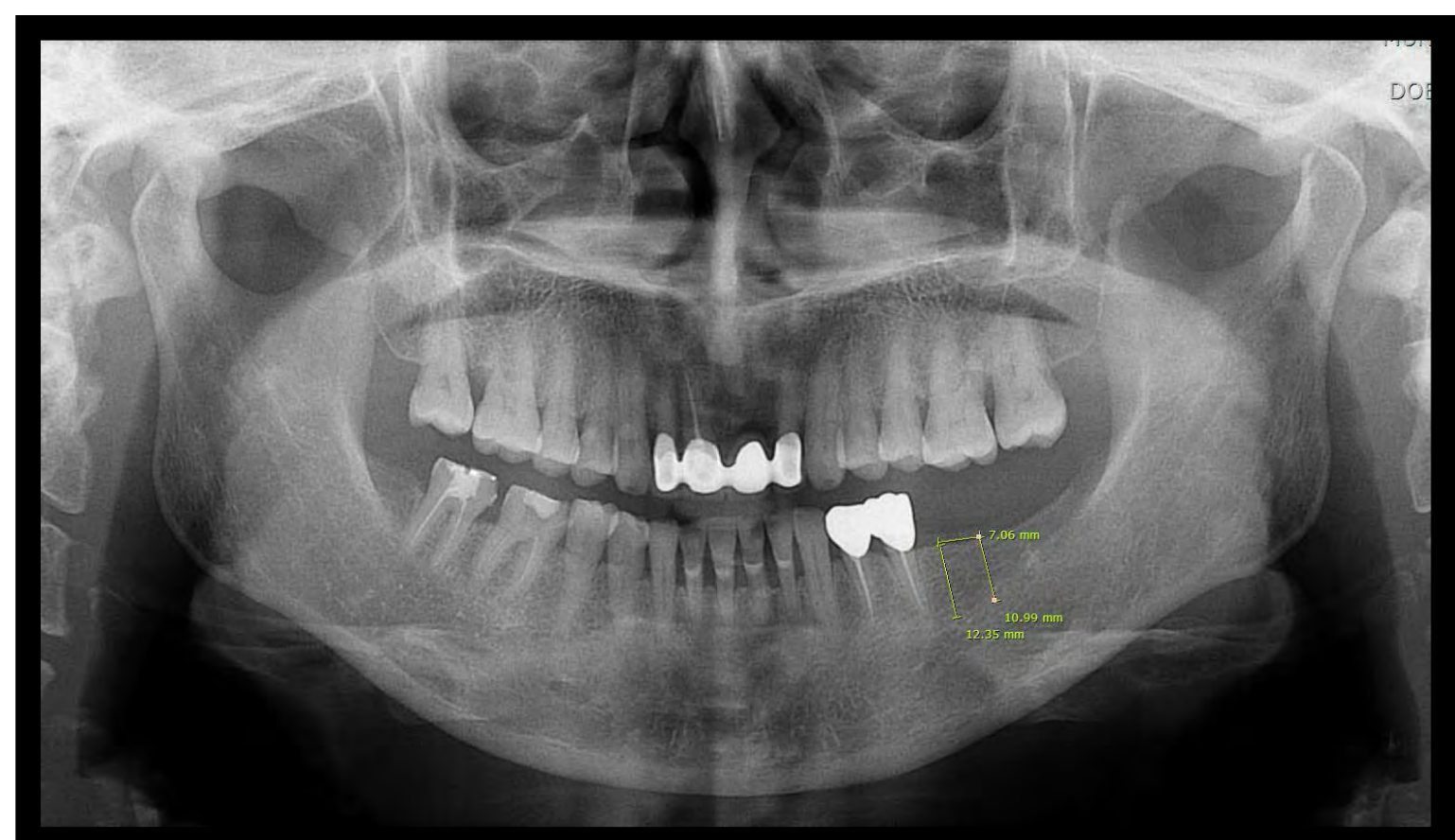


Fig. 1. Direct digital (CCD) panoramic radiograph

3. CBCT reformatted panoramic images

- Dental Cone-Beam CT (DCT pro; VATECH KOREA)
- Panoramic images reformatted using **SimPlant** materialize dental software

► Create panoramic curve

- Mx.- center of maxillary alveolar ridge(Fig. 2.)
- Mn.- center of mandibular alveolar ridge at the level of mental foramen(Fig. 3)

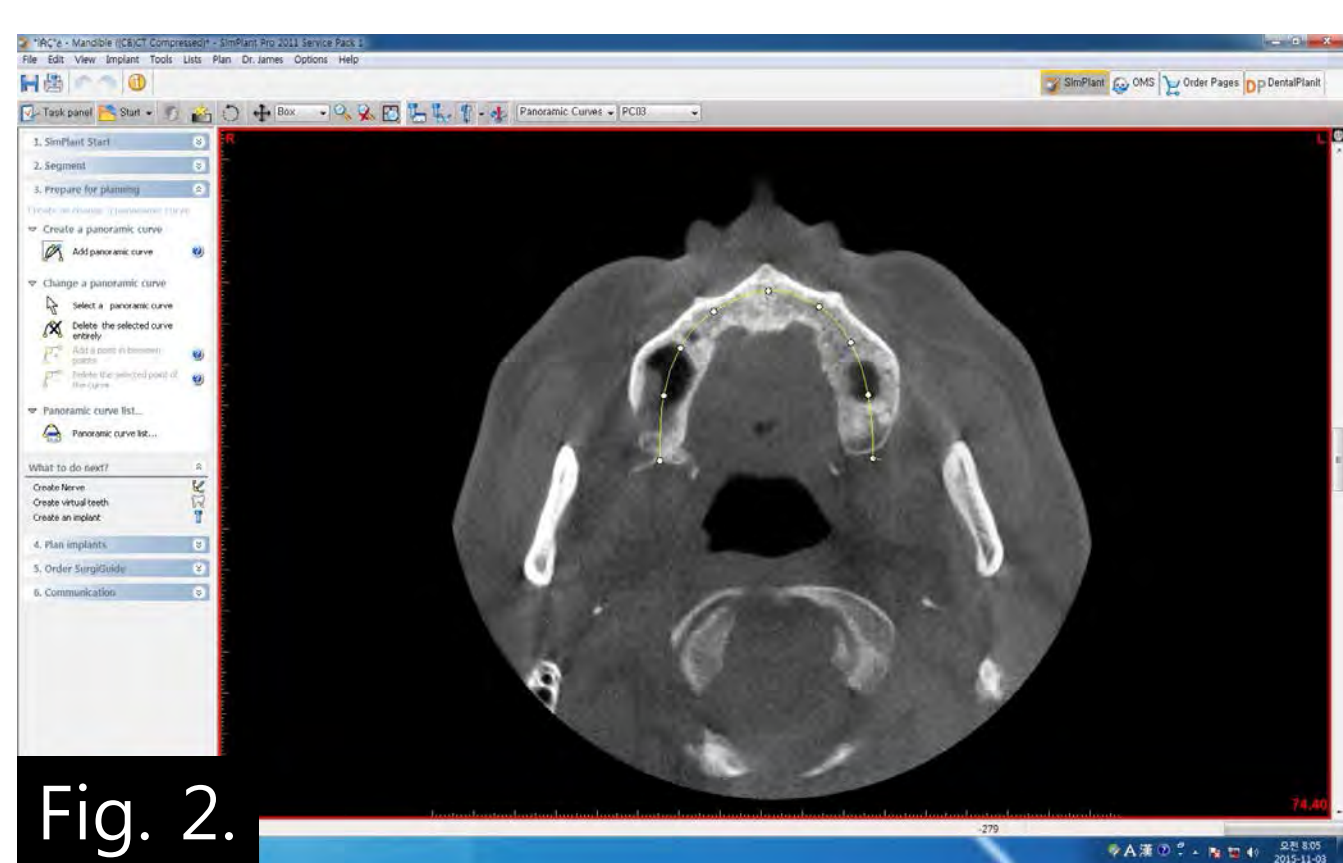

Fig. 2.

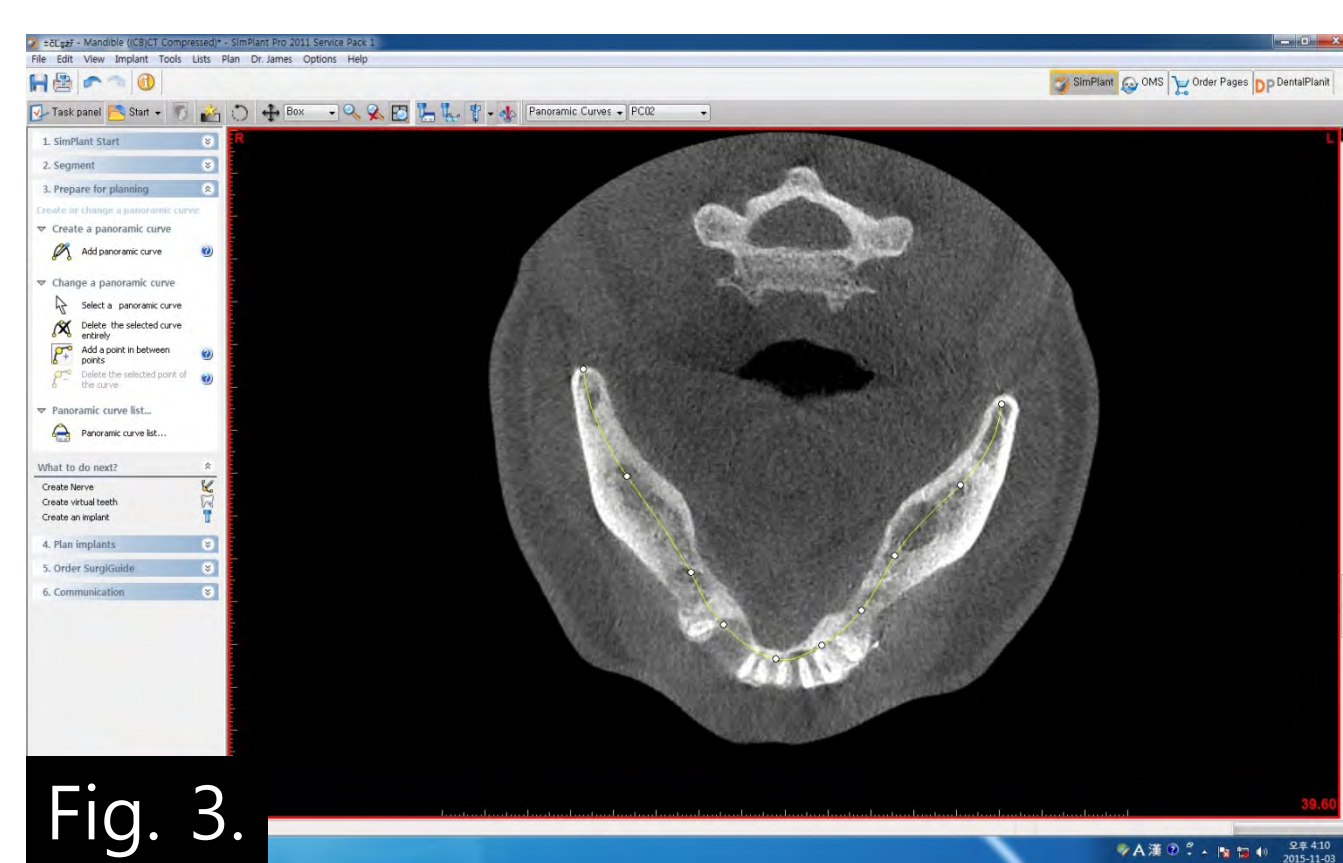

Fig. 3.

► Length measurement criteria

- Mx.- alveolar bone crest ~ inferior border of sinus
- Mn.- alveolar bone crest ~ inferior alveolar nerve at premolar & molar regions

RESULTS

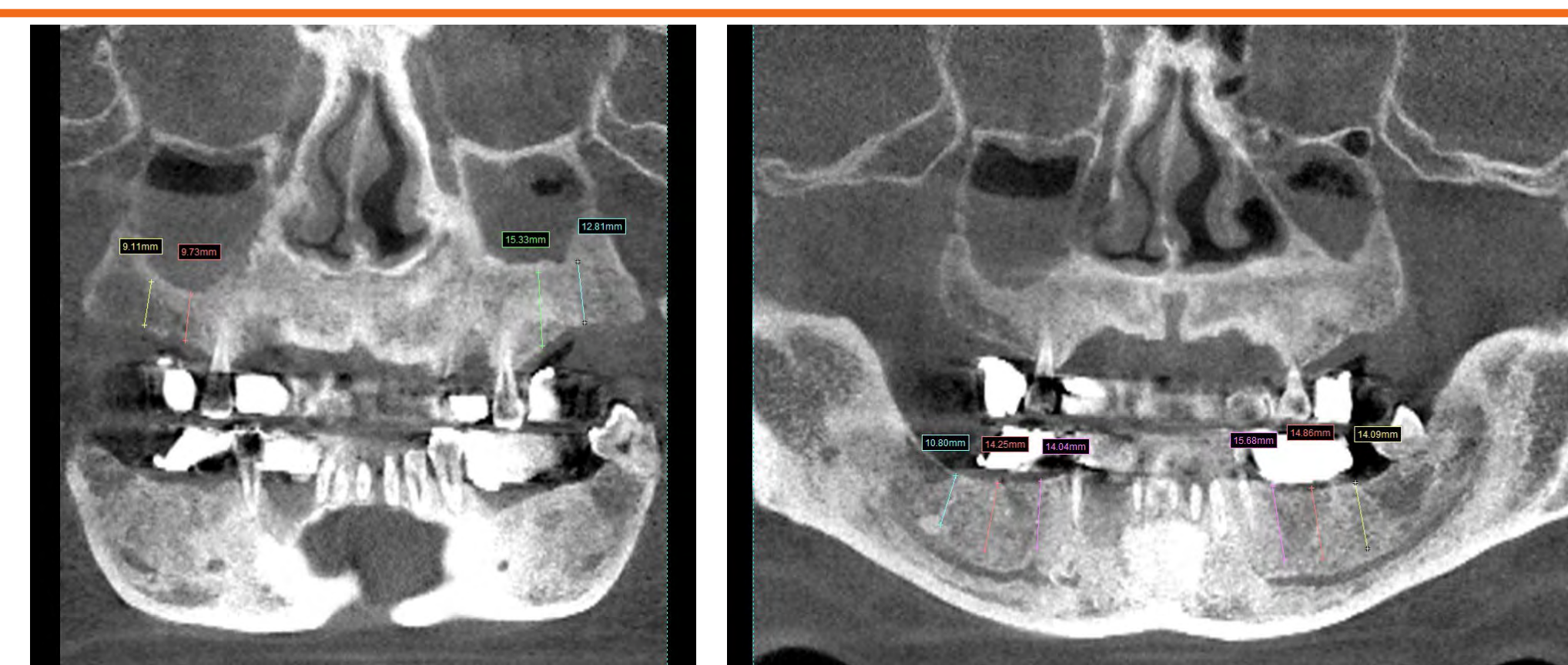


Fig. 4. A CBCT reformatted panoramic radiograph

Table 1. Length measurements

Implant site	PANORAMA	CBCT Reformatted	Implant site	PANORAMA	CBCT Reformatted	Implant site	PANORAMA	CBCT Reformatted	
#14	13.96	12.83	#24	12.32	16.67	#35	17.26	15.68	
	11.49	11.93		8.32	9.18		#36	17.55	14.86
	12.99	10.69		#25	14.38		13.35	15.92	11.58
#15	6.55	5.59	10.33		14.93	12.35	11.8		
	8.91	10.34	#26		11.84	15.33	#37	16.85	14.09
	12.69	16.69		8.15	8.38	14.45		9.56	
7.48	9.93	8.68		11.53	10.99	9.96			
#16	11.59	9.73	#27	8.63	4.42	#45	15.35	14.04	
	5.38	2.59		7.02	12.81		#46	17.24	14.25
	8.42	9.87		6.45	5.18		15.19	10.41	
#17	11.64	12.67	#28	9.51	16.61	#47	16.47	10.8	
	6.96	4.81		4.85	5.16		13.88	10.63	
	9.3	9.11							
	10.79	10.21							
	9.65	12.69							
	10.19	5.09							
	6.54	4.61							

Length measurement error (mm)	N
0 ~ 1.0	8
1.0 ~ 2.0	11
2.0 ~ 3.0	6
3.0 ~ 5.0	12
≥ 5.0	5

N= number of implant site

- 1) Length measurement error appears to vary from 0.19 ~ 7.1mm. The average error was 2.65 mm.
- 2) In mandible, the length was measured longer on all implant sites digital panorama than CBCT reformatted panoramic images, however, in maxilla it depends on the case.

DISCUSSION

Accurate preoperative implant planning is very important. Through radiographs, operators predict the length of implant placement. In CBCT reformatted panorama view, the exact length measurement is possible because of the anatomical structures clearly seen. The CBCT reformatted panoramic images outperformed the digital panoramic images. Due to the fact that the CBCT images were reformatted slices of the maxilla and mandible, they were free of magnification, superimposition of neighboring structures, and other problems inherent to panoramic radiology.

In maxilla, because sinus lift patients are excluded, it did not show significant differences in the length measurement. In panorama, IAN is not clearly seen. Measurements that are over 10mm length in digital panorama, these are measured shorter in CBCT reformatted panoramic images because of clear nerve position.

If the length is insufficient (over 10mm) in digital panoramic view, CBCT exam is considered to be necessary especially in mandible.