


Fixed Immediate Temporary Dentures for Edentulous Jaws Made by CAD/CAM Fabrication with the COMFOUR System.

Schnutenhaus S.^{1,2}, Edelmann C.¹, Luthardt R.G.²

¹ Private practice, Hilzingen, Germany

² Department of Prosthodontics, University of Ulm, Germany



Objectives

In a case series the CAD/CAM process of fixed immediate dentures including 3D-planning, fabrication and integration of the temporary restoration will be introduced.

Material and Methods

The newly developed COMFOUR System offers the clinician to provide fixed restorations for edentulous patients using the Malo treatment protocol and ensure a safe and a prosthetically oriented outcome. Template-guided implantation is recommended to optimally use local bone without the need for augmentation and to insert the implants in prosthetically ideal positions. By superimposing the STL data of the diagnostic wax-up and the CBCT data of the patient the

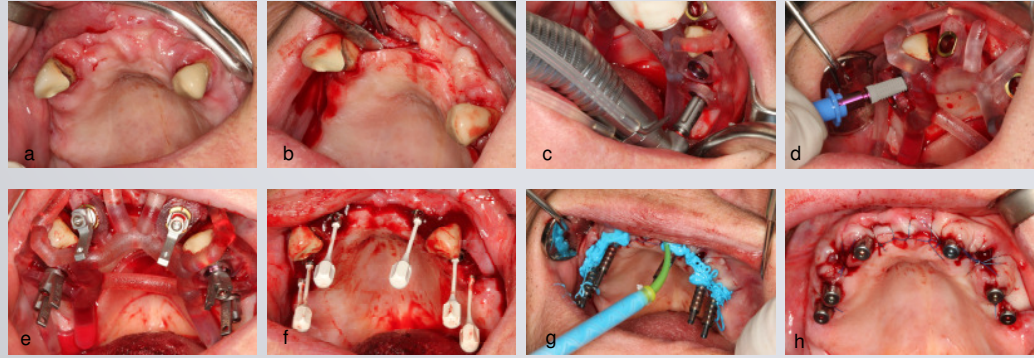


Fig. 1: Surgical protocol: intraoral situation before treatment (a), implant site preparation (b), template guided implantation (c), implant insertion (d), aligning tool (e), flexible handle (f), impression (g), implants with healing caps (h)

ideal positions of the implants can be virtually chosen and a stereolithographic template is fabricated including the three dimensional information of the implants. All emerged data in this process (digital model, diagnostic wax-up and virtual implant position) are used for the digital design of the temporary therapeutic denture. The STL data of the construction design is sent to a milling center (DEDICAM) fabricating the temporary therapeutic denture with an eligible material (Telio-CAD).

Results

After implantation the temporary restoration can be finished by veneering titanium caps optionally on the bar lab analog on a working model or on the definitely in the implant inserted bar abutments. The complete temporary restoration is then fixated to the bar abutment with prosthetic screws. The final delivery of the temporary restoration can be scheduled only a few hours after insertion of the implants.

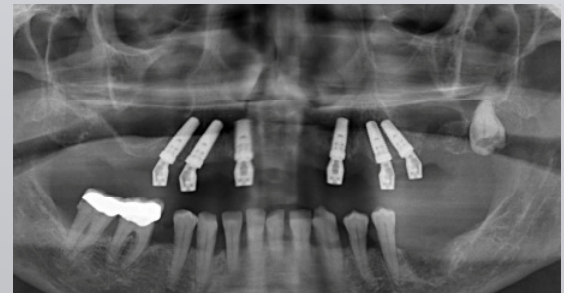

Fig. 4: Orthopantomogram taken after implantation

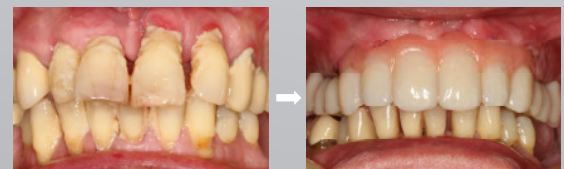

Fig. 5: Intraoral situation before (left) and after (right) treatment

Conclusion

This approach allows the dentist to achieve a functional and esthetic temporary therapeutic denture finished on the day of surgery. Furthermore, the use of a biocompatible, comfortable and stable material ensures good oral hygiene. The advantage of the consequent CAD/CAM workflow is the fact that it provides all steps needed in the process, thus neither additional treatment time nor additional laboratory time, increasing the costs, are necessary.

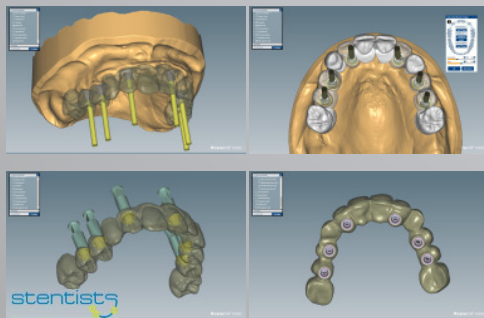


Fig. 2: Digital construction of the temporary restoration

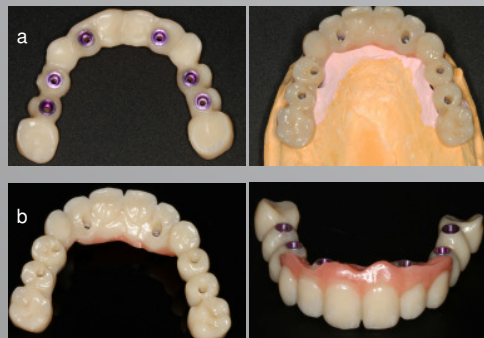

Fig. 3: Laboratory steps: titanium caps are placed into the temporary restoration by veneering after adaption on the working model (a), finished temporary restoration (b)

Contact:

Dr. Sigmar Schnutenhaus MSc,
 Department of Prosthodontics, University of Ulm
 Albert-Einstein-Allee 11, 89081 Ulm, Germany
 sigmar.schnutenhaus@uniklinik-ulm.de