

Management of Extractions Sites - A New Approach for Compromised Conditions in the Posterior Maxilla

Roman Beniashvili, DDS, Dr. med dent, Bastian Kern, DDS, Dr. med. dent.

Tagesklinik für Oralchirurgie, Mund-, Kiefer-, Gesichtschirurgie und Implantologie Dr. Roman Beniashvili und Prof. Dr. Dr. Konrad Wangerin, Schorndorf, Germany

Introduction

In unfavorable situations, like maxillary atrophy and/or distinct pneumatization of the maxillary sinus in combination with an attachment loss of the teeth due to advanced periodontal disease, leading to severe vertical bone loss, new therapeutic modalities are needed. Preservation or even improvement of the height and width of the alveolar ridge is essential in order to avoid or reduce the frequency and size of augmentation procedures [1,2]. The aim of the presented technique was to reduce the need of augmentation and avoid the sinus floor elevation or at least to provide treatment options for a one-stage approach when at the time of tooth removal a deficit in the alveolar bone could already be expected and the need of a later sinus lift procedure was conceivable.

Materials and Methods

The described technique, which is the modification of a technique described by Fugazotto [3] was performed in 10 sockets following tooth extraction (7 molars and 3 premolars) in 7 patients. All ten patients were female with an age ranged between 32 to 74 years. Tooth extraction was performed with special care minimizing trauma to the surrounding hard and soft tissues. Therefore, a sulcular incision was made around the tooth to preserve the approximal papilla structure. Preserving the interradicular bone and the buccal wall in case of molars and premolars with two roots, the tooth was trisected/bisected and the roots were gently removed individually (Figs. 1 - 3). Based on the radiographs and the existing clinical situation, a calibrated trephine bur was used, which was in sufficient dimension to include the complete interradicular septum and at least 50% of the extraction socket, but kept a minimum distance of 1.5 - 2 mm to adjacent teeth and 1mm to the buccal and palatal walls. Utilizing preoperative radiographs and measurements, a site was prepared using the trephine bur to within approximately 2 mm of the sinus floor (Figs. 4 - 5). In cases of premolars and molars without interradicular bone, and tapered roots, an appropriate dimension of the trephine bur, was selected to reach the socket walls 3 - 4 mm before the expected maxillary sinus floor. Osteotomes selected corresponding the diameter of the trephine preparation. The osteotomes were used under gentle force of a mallet, to a depth of 3 - 5mm. The residual socket was filled with a slowly resorbing, xenograft (Bio-Oss®) (Fig. 6). Because of the existence of the buccal wall, no membranes were used. In order to avoid to mobilize the mucogingival line coronally and to create a thick and adequate soft tissue, mucoperiosteal flap elevation was not used for wound closure. Sockets were closed by free or connective gingival grafts / tissue grafts (palatal pedicle tissue) (Fig. 7).

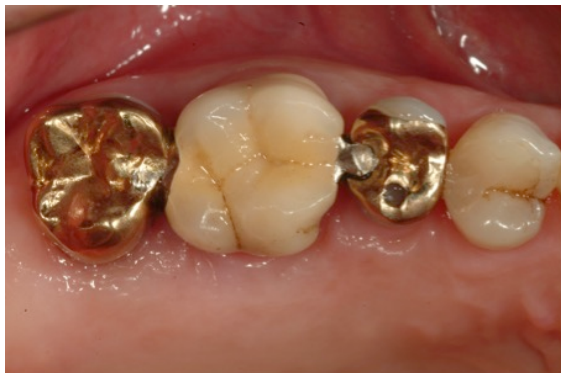

Fig. 1: initial clinical condition

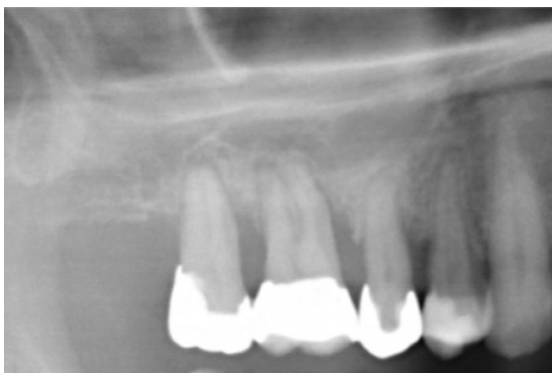

Fig. 2: preoperative radiograph

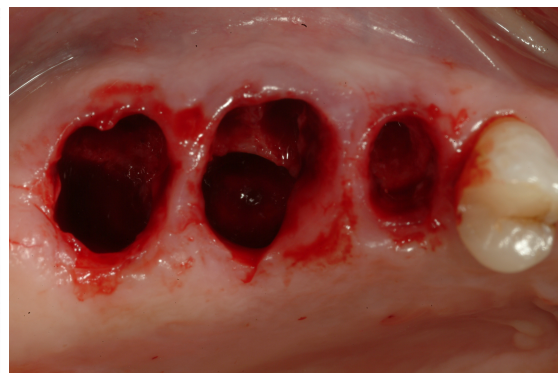

Fig. 3: Extraction sites

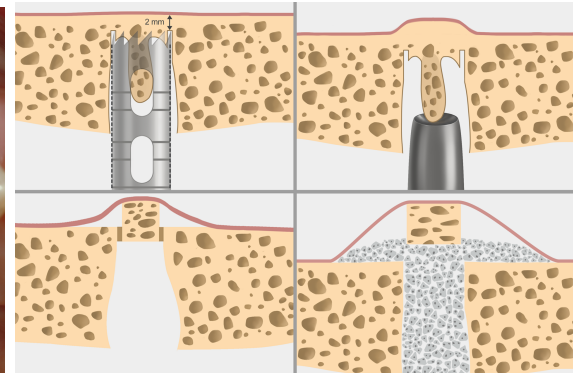


Fig. 4: surgical technique

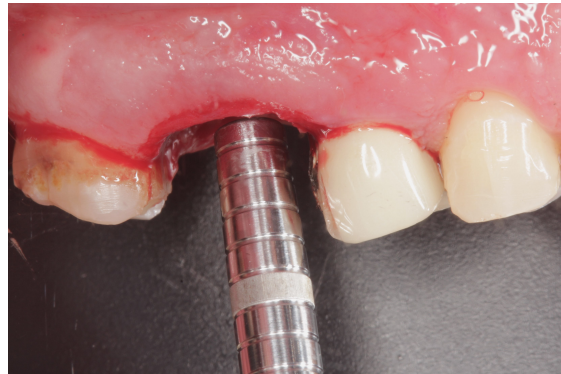

Fig. 5: Osteotome

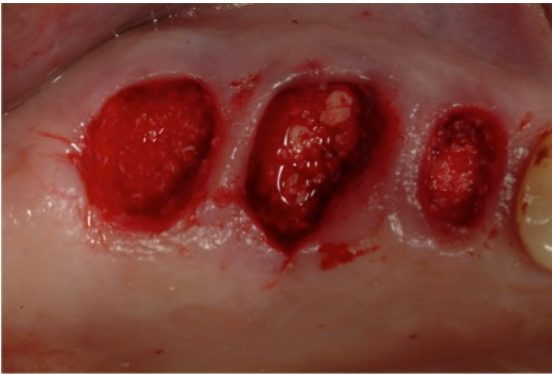


Fig. 6: augmented Extraction sites

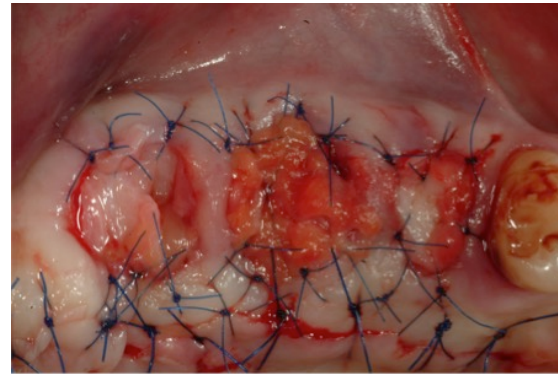


Fig. 7: connective tissue graft (tunnel technique)

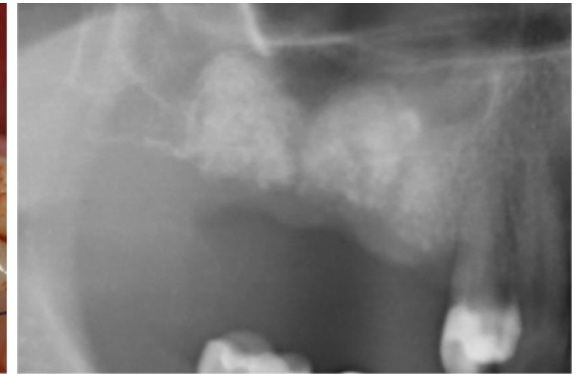

Fig. 8: radiograph 3-months postoperative

Results

After a 3-month healing period, average vertical bone dimensions measured 10.2mm (7.1mm - 13.8mm). In comparison with preoperative condition, an average increase of the primary sub-antral bone height of 3.4mm (1.2 - 7.6mm) was observed. The number of regions with vertical bone dimensions < 7mm was 0. According to this, the number of cases with an indication for an external sinus floor elevation was reduced by 100% (7 vs. 0) [4]. 10 Camlog® - implants with lengths from 11 - 13mm were placed, such as: one 3.8 x 11mm, one 4.3 x 11mm, two 5.0 x 11mm, three 6.0 x 11mm, two 4.3 x 13mm, and one 5.0 x 13mm implant (Figs. 8 - 10). All implants were mechanically stable. Considering that the minimum length of the implants was 11mm, implants were placed in combination with an osteotome sinus floor technique in 6 cases (60%). The average sub-antral bone height, prior to sinus floor elevation was 8,7mm (7.1 - 10.5mm). In no case (0%), the implant placement was performed utilizing a simultaneous conventional sinus floor elevation with lateral window and no additional vertical augmentation was indicated. In no case was a two-step procedure for sinus floor elevation necessary. An additional lateral augmentation procedure was performed in three cases (33.3%); in one case due to presence of a dehiscence and in 2 cases to prevent resorption of a thin buccal wall. After a healing period of 3 months, all 10 implants were uncovered. No further soft tissue corrections were needed, second stage surgery was performed, minimally invasively, or just with a small apically positioned flap. All implants were restored. Single-crown restorations or fixed bridges were placed on all implants. Osseointegration and periimplant health were evaluated at the time of implant uncovering and after restoration using radiographs, clinical examination and stability tests (Periotest). All implants were clinically stable at the time of uncovering and examination after restoration (Figs. 11 - 12). The Periotest values were between -8 and -2 (average: -5).

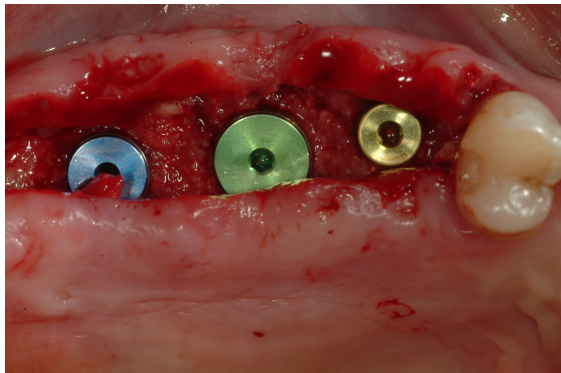


Fig. 9: Implant placement

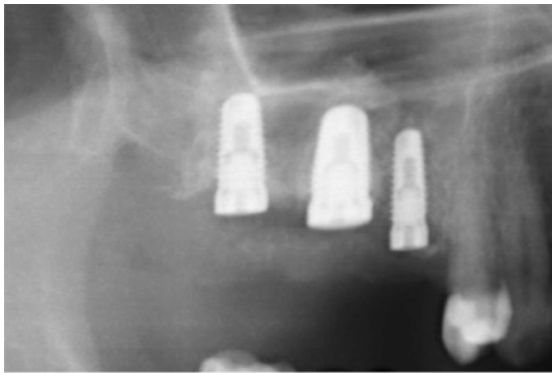


Fig. 10: radiograph at the time of implant placement

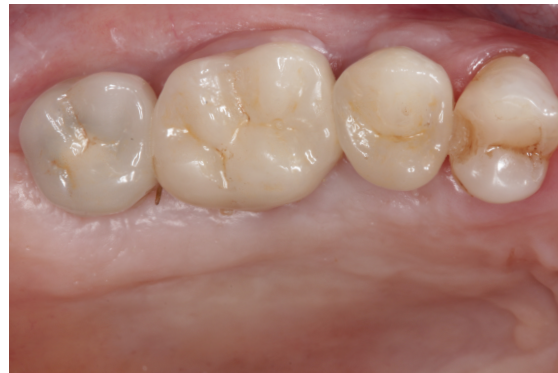

Fig. 11: Final Restoration

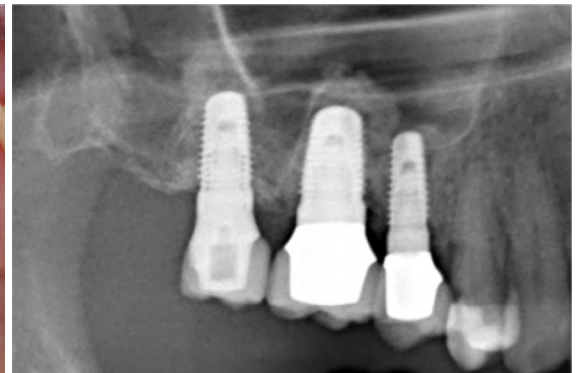


Fig. 12: 4-year follow-up

Disclosure

The described procedure verified that it improves the clinical condition for future implant placement in compromised initial situations, when distinct alveolar defects and reduced residual bone height are expected.

Literatur

1. Araujo et al. (2008) Influence of Bio-Oss Collagen on Healing of an Extraction Socket: An Experimental Study in the Dog. *International Journal of Periodontics and Restorative Dentistry* 28: 123-135.
2. Weng et al. (2011) Welche Massnahmen sind sinnvoll zum Strukturhalt des Alveolarfortsatzes nach Zahnextraktion? *European Journal of Oral Implantology* 4: 123-130.
3. Fugazotto PA (1999) Sinus Floor Augmentation at the Time of Maxillary Molar Extraction: Technique and Report of Preliminary Results. *International Journal of Oral and Maxillofacial Implants* 14(4): 536-542.
4. Jensen SS, Katsuyama H Preoperative Assessment and Planning for Sinus Floor Elevation Procedures. *ITI Treatment Guide Volume 5 - Sinus Floor Elevation Procedures*.

The authors declare no financial interest in any of the products mentioned herein. The authors mention their gratitude to dentist Horst Dieterich for the prosthodontics in the case herein.

Tagesklinik für Oralchirurgie, Mund-, Kiefer-, Gesichtschirurgie und Implantologie Dr. Roman Beniashvili und Prof. Dr. Dr. Konrad Wangerin, Schorndorf, Germany.

www.dr-beniashvili.de