


# IMMEDIATE LOADING WITH CAMGUIDE IN ANTERIOR ESTHETIC ZONE WITH SOCKET GRAFTING

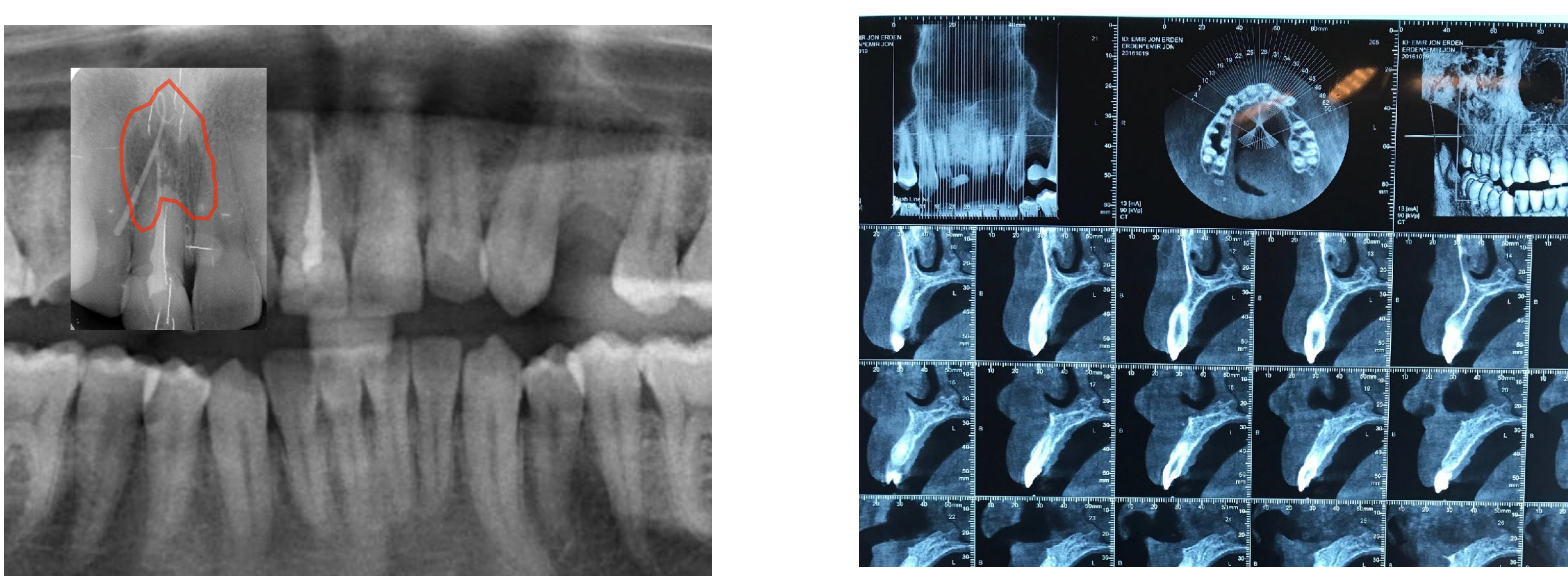
**SELIM PAMUK** PGG Dental Clinic, Istanbul, Turkey  
**ASLAN GOKBUGET** PGG Dental Clinic, Istanbul, Turkey  
**BEHIYE BAHAR DABAKOGLU** Kavram Vocational School Department of Dental Technologies; Istanbul, Istanbul, Turkey

## Case presentation

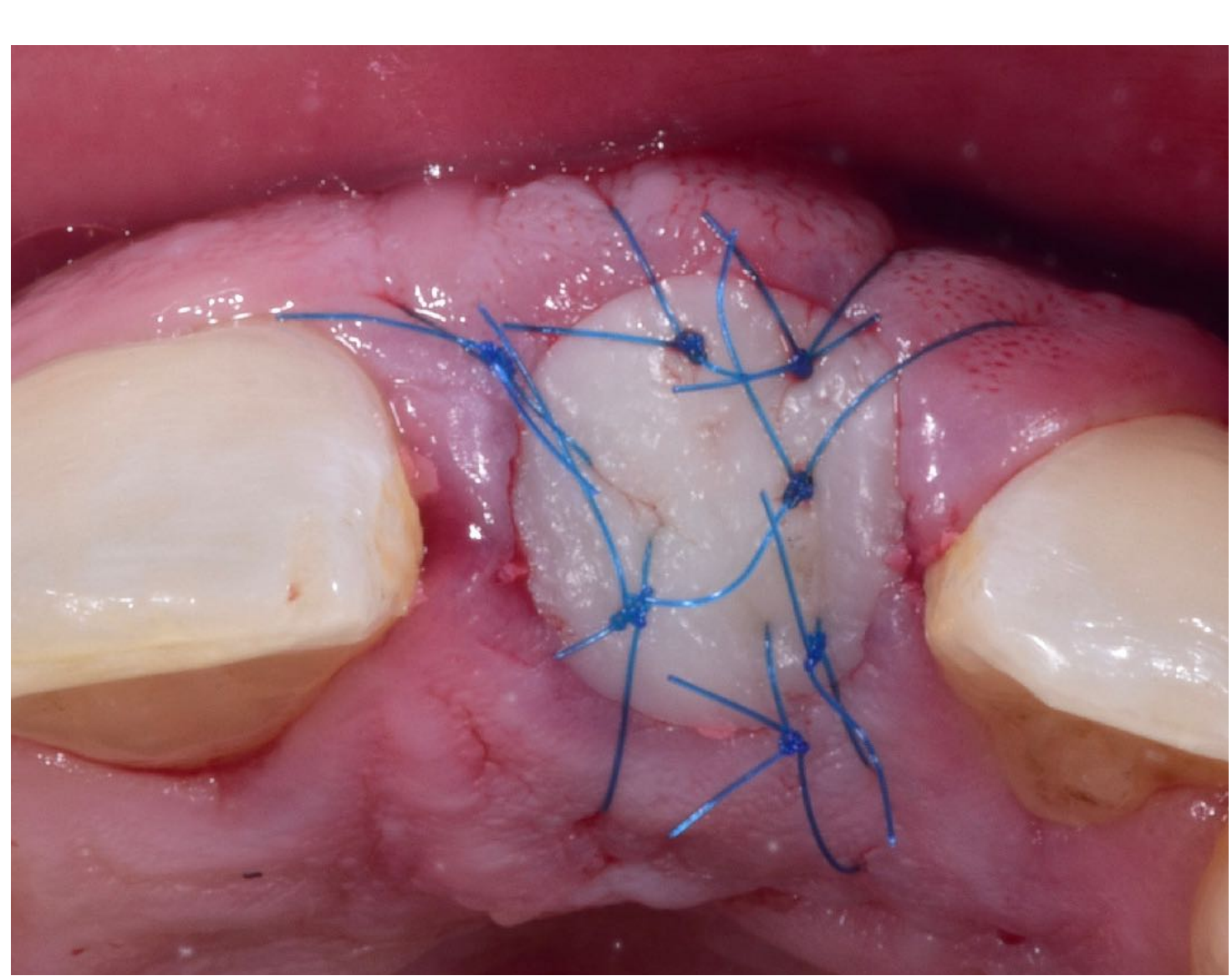
Patient came to our office regarding recurrent infection on #11. After carefull clinical and radiographical examination it is decided to extract the tooth and perform socket augmantaion procedure. Four months later implant placement is done with the help of Camguide. After the insertion of the implant, a CAD/CAM abutment over a Ti base and and a temporary crown is produced with CEREC. 4 months later temporary restoration is replaced with a definitive CAD/CAM e-max crown.





Initial situation



Panoramic and CBCT





Socket preservation







Temporary adhesive bridge at the healing period

Healing completed and Camguide is used



Implant inserted


Scan body, CAD/CAM abutment, temporary crown




Abutment in place

Final x ray

Final e-max restoration



Temporary Crown



Definitive Crown