



Innovative Approach for the Treatment of a Severely Atrophic Maxillary Edentulous Ridge

Eric S Morrison, DDS PA

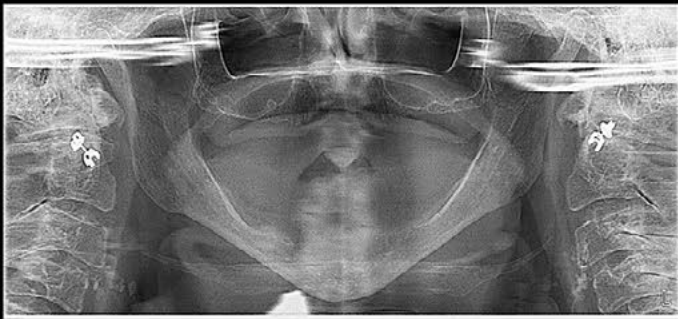
Waynesville, North Carolina USA

Goal

To provide my patient with an acceptable upper and lower Denture to comfortably eat a North Carolina "Pulled-Pork" Barbeque Sandwich.



Observations



1. Severe atrophic Maxillary and Mandibular ridge
2. Hyperplastic gingival tissue unsupported by Maxillary alveolar bone
3. Dislodging of posterior palatal seal upon incisal loading
4. Use of upper and lower dentures mainly for aesthetics
5. Vertical wrinkling of the upper lip and corners of the mouth drooping
6. Yellow dentition

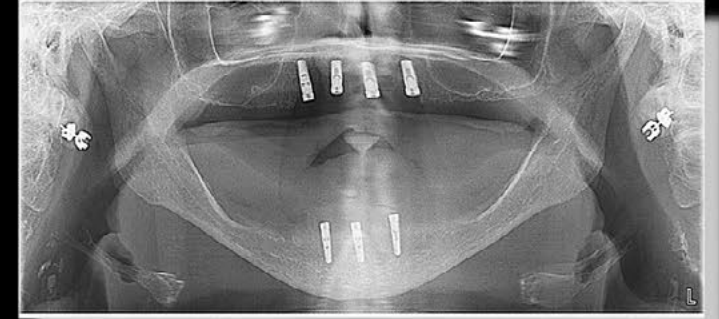


Patient presented with loose Dentures that dropped when she talked and gagged her upon swallowing. She was referred for Bone Grafting and said "I'm Not going to do that". "I Can't eat the foods I want", "especially a North Carolina Pulled Pork BBQ Sandwich" and "I'm not going to have that Bone Surgery". "Help me DOC!"

Materials & Methods

7 CAMLOG implants (4 on Maxilla, 3 on Mandible), Precision fit CAD/CAM Maxillary ridge augmenting Belgium Bar with locator attachments. Metal framework Maxillary "horseshoe shaped" Denture. Metal framework Mandibular Denture over 3 single locator abutments

Treatment

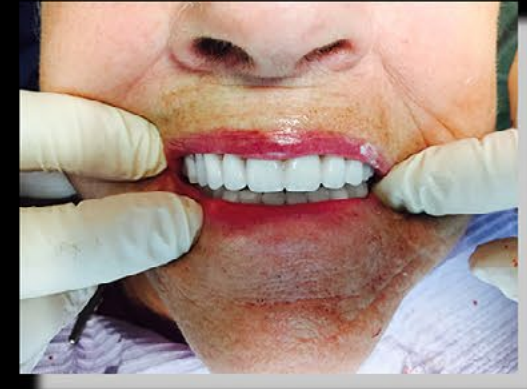
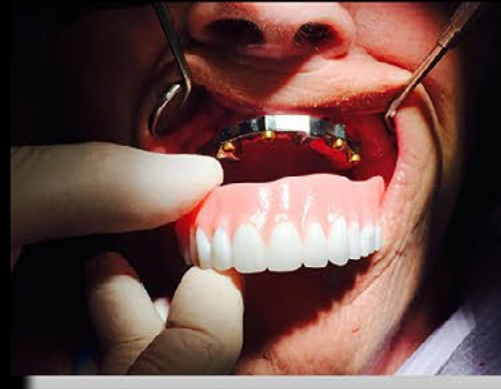
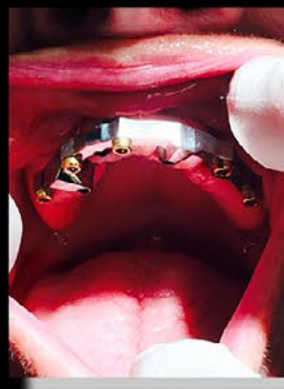Panoramic x-ray taken 6 months postoperative showed solid osseointegration.

Past Medical History within normal limits, Local Anesthetic 4% Articaine 1/100,000 epi x 7.2cc. Full thickness flap upper and lower ridges. 4 Camlog implants placed in 5,7,10 & 12 location. 3 Camlog implants placed in 22,24/25 & 27 anatomical areas. Flap closed with 4-0 gut suture and postoperative penicillin 500mg given 2 stat then 4 times daily for 7 days. Vicoprofen 7.5/200 as needed for postoperative discomfort. Patient advised to return for postoperative check in 7 days and wear interim dentures with soft diet.

Methods

Healing caps exposed and open-tray impregum impression tray technique preformed. Verification jig confirmed impression of analog placement in stone model and bite registration verified occlusion. Maxillary and Mandibular Over-dentures with retrofitted locator Housings made to accurately fit locator attachments on Maxillary bar and Mandibular abutments. Torqued Maxillary bar 30nm. Inserted Full upper and lower Dentures over bar and occlusion equilibrated. Patient advised to wear 24/7 for 30 day adjustment period and only take out to clean.



Patient reported first time in 15 years she was able to eat a North Carolina Pulled Pork BBQ Sandwich.

