



BACKGROUND

The insufficient bone height in the posterior maxilla is a common problem after the loss of posterior maxillary teeth. For posterior implant sites with complex bone defects, we need to apply lateral window sinus elevation and guided bone regeneration, to restore the patient's bone height.

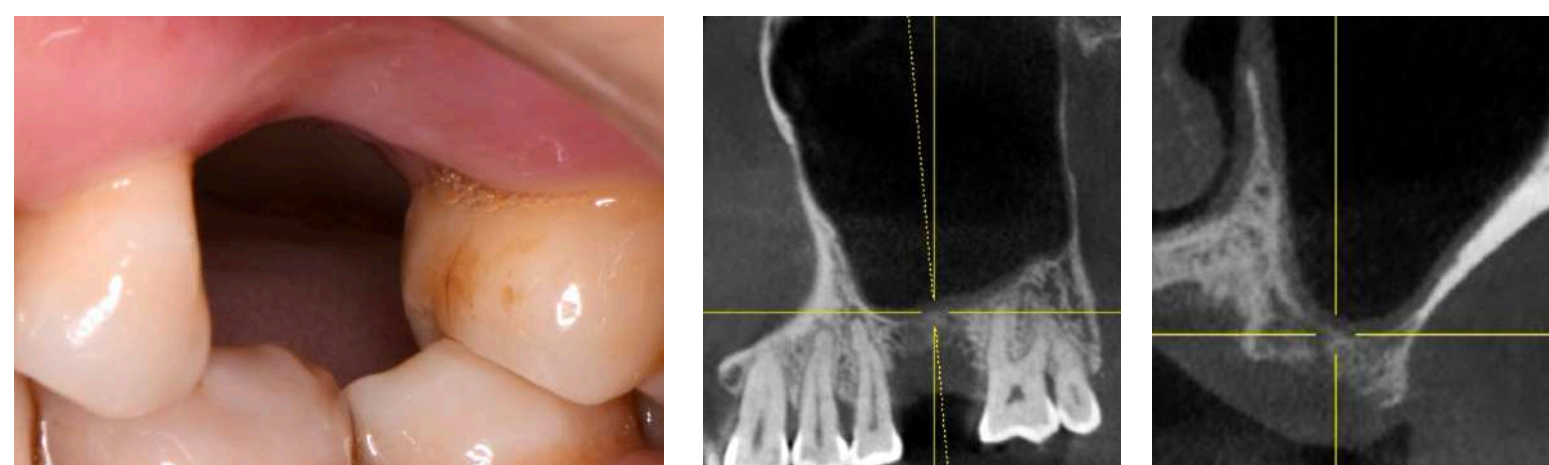
AIM

To repair bone height deficiency at the posterior missing tooth site of inclined alveolar crest.

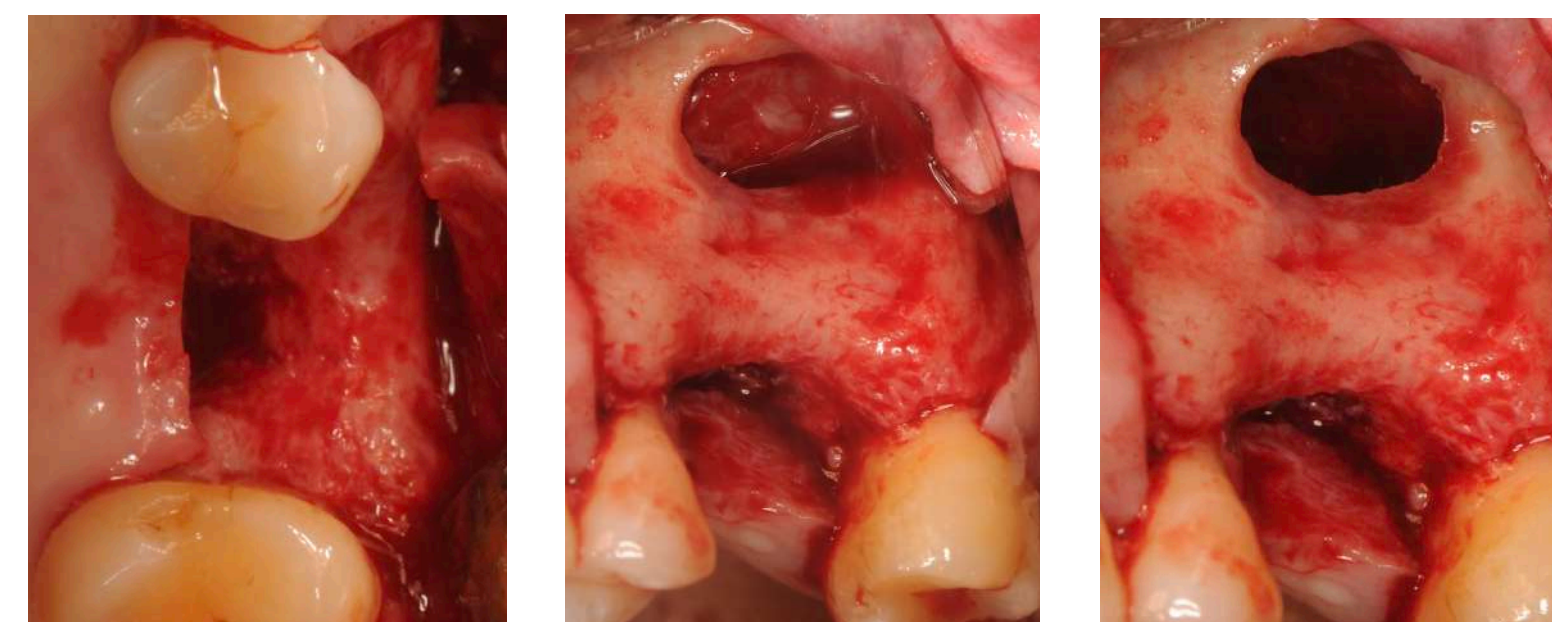
MATERIALS&METHODS

a) clinical data: A 43-year-old female patient had her tooth 26 extracted 6 months ago. Patient was in good systemic condition and had no history of systemic disease or food/drug allergies.

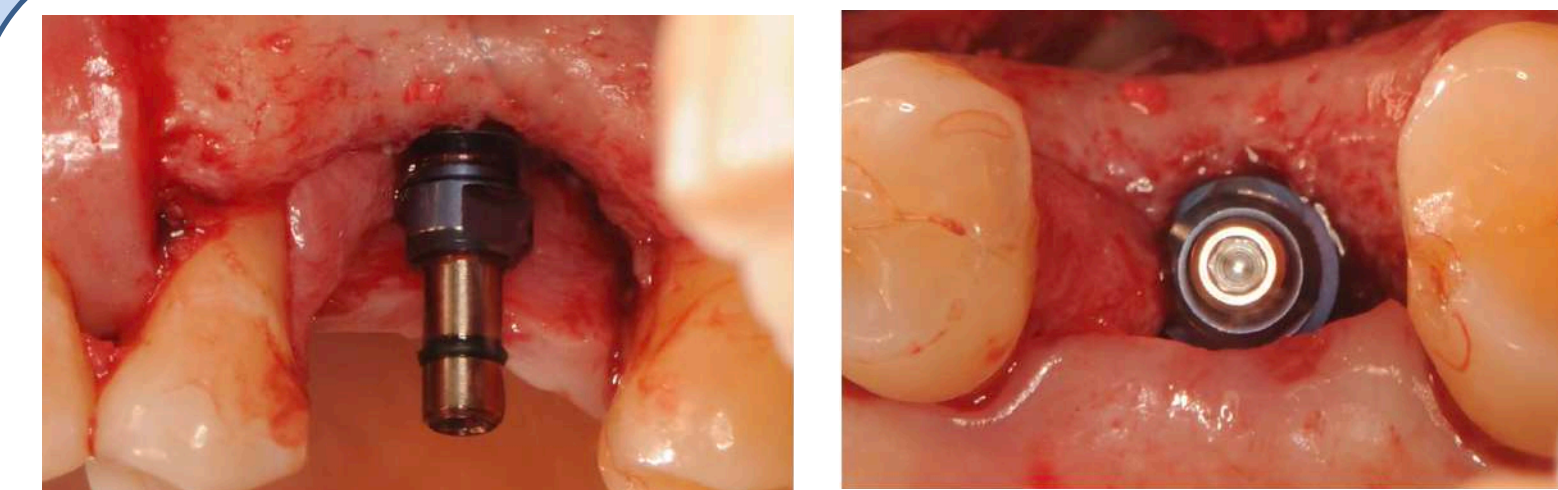
b) Examination: Tooth 26 was Missing, attached gingiva was in good condition. CBCT showed that the available bone height of 26 missing tooth sites was about 3.5mm, and the maxillary sinus floor was flat, Lingual oblique alveolar crest, low bone density.



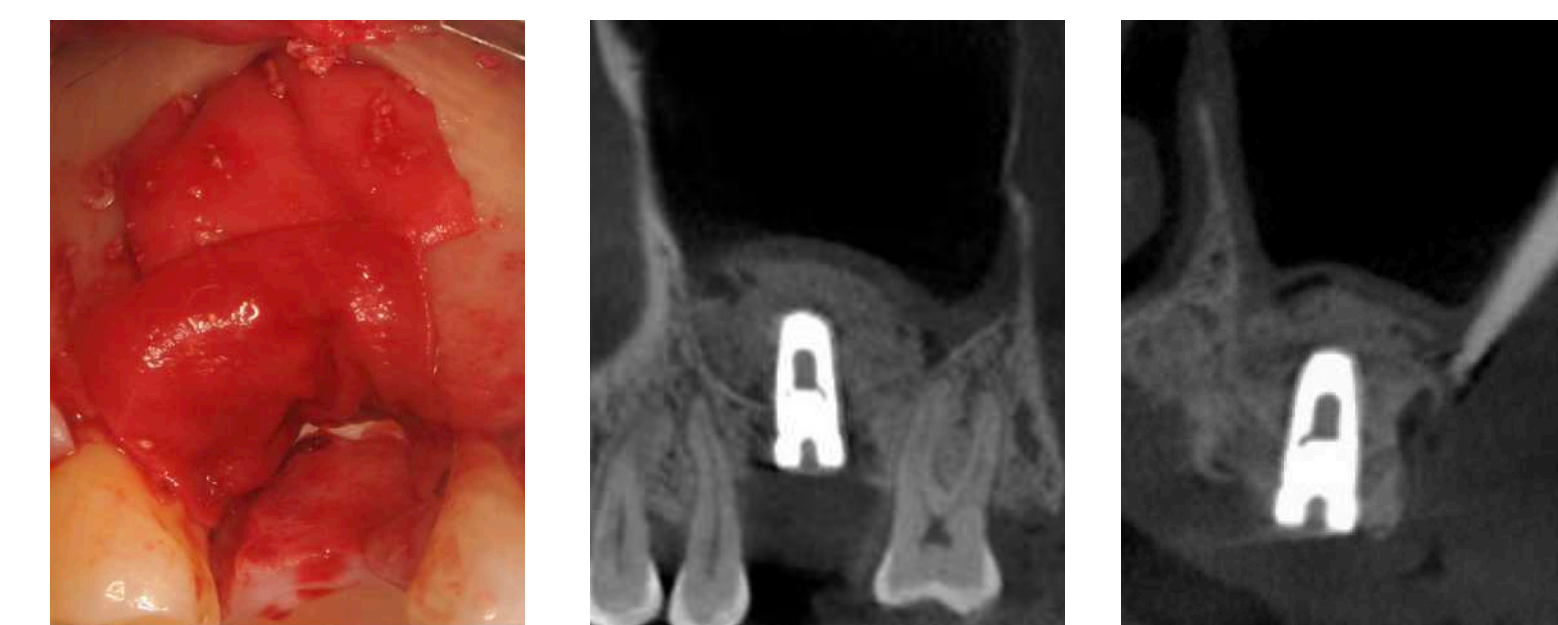
- c) Diagnosis: 26 missing
d) Treatment: 26 Implant placement with simultaneous maxillary sinus floor elevation and guided bone regeneration, Conventional restoration.
e) Material:
Implant system: CAMLOG® SCREW-LINE implant, Promote® ø5.0mm, 11mm (CAMLOG®, German), bone substitute: DBBM 0.25g small particle (Bio-Oss® Gestlich, Switzerland); resorbable collagen membrane 13*25mm (Bio-Gide® , Gestlich, Switzerland).
f) Surgical procedure:
Flap elevation procedure was performed at tooth #26. Open a window in the lateral wall of the maxillary sinus, and the sinus mucoperitoneum was carefully removed under endoscopy.



A mixture of Bio-Oss@ bone graft and autologous bone chips(8:2) was implanted into the maxillary sinus floor and on the palatal side of crest along with the dental implant.

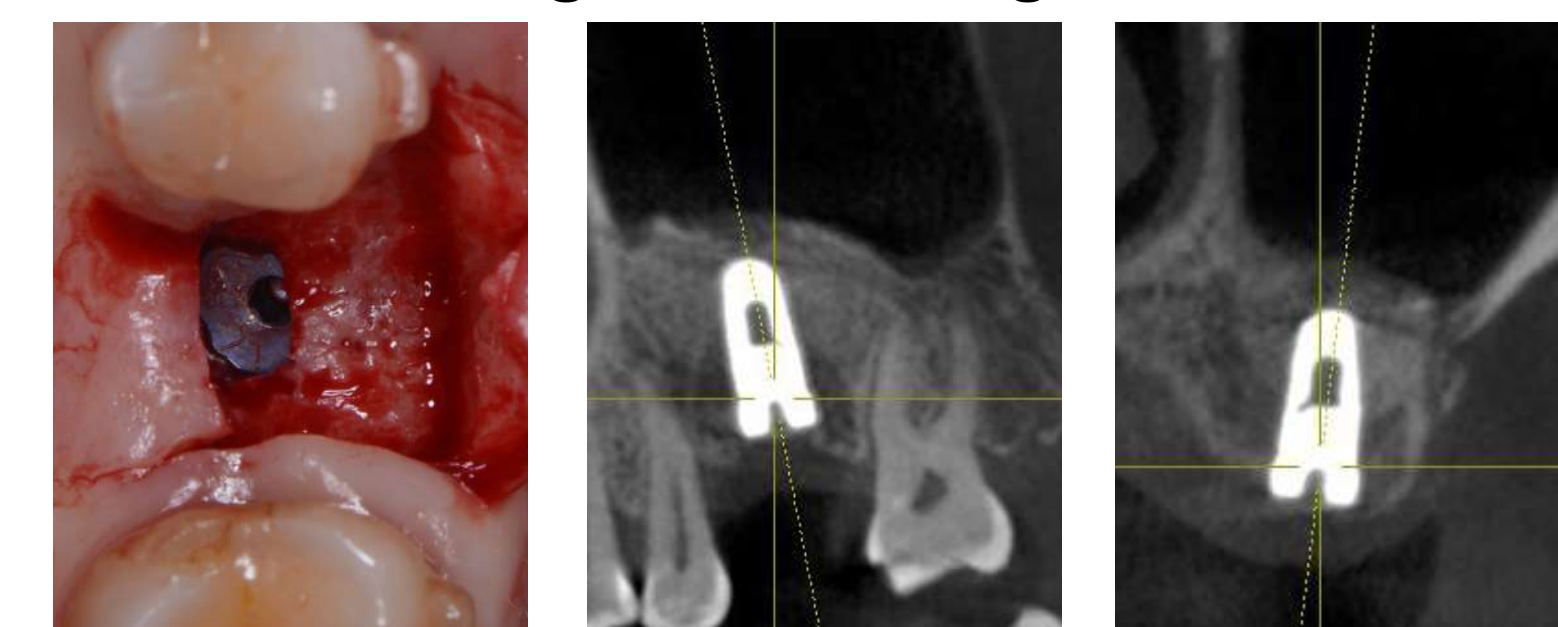


The implant was covered with a closure screw. A small amount of bone graft material was also implanted on the palatal side of the implant. The absorbable barrier membrane was then placed over the bone window and the crest of the ridge. Wound closure was performed without tension. The CBCT showed good implant position and sufficient bone augmentation volume.

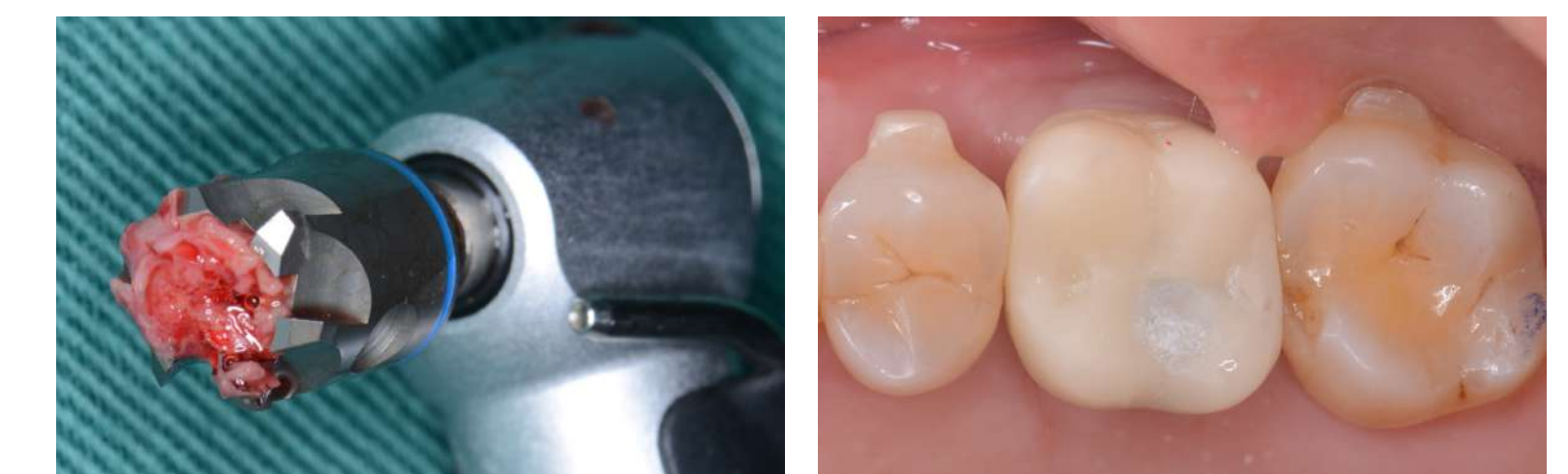

RESULTS

Nine months later, new bone had formed around the coronal aspect of the implant. CBCT showed good bone regeneration result.



Bone profile was used to help remove the tissue and expose the Implant platform. ISQ (Implant Stability Quotient) value was 80. However, due to the patient's ongoing orthodontic treatment, a resin provisional restoration was used as an interim solution. The final restoration will be completed once the orthodontic treatment has been successfully concluded.



CONCLUSIONS

We employed a combination of maxillary sinus floor elevation and GBR techniques to restore bone volume for the patient. The neck of the implant can accommodate different buccal-palatal bone heights and achieve excellent initial stability, simplifying the surgical procedure.



This QR code for a video of the Surgical procedure about this case.

DISCLOSURE OF INTEREST

There is no conflict of interest.