

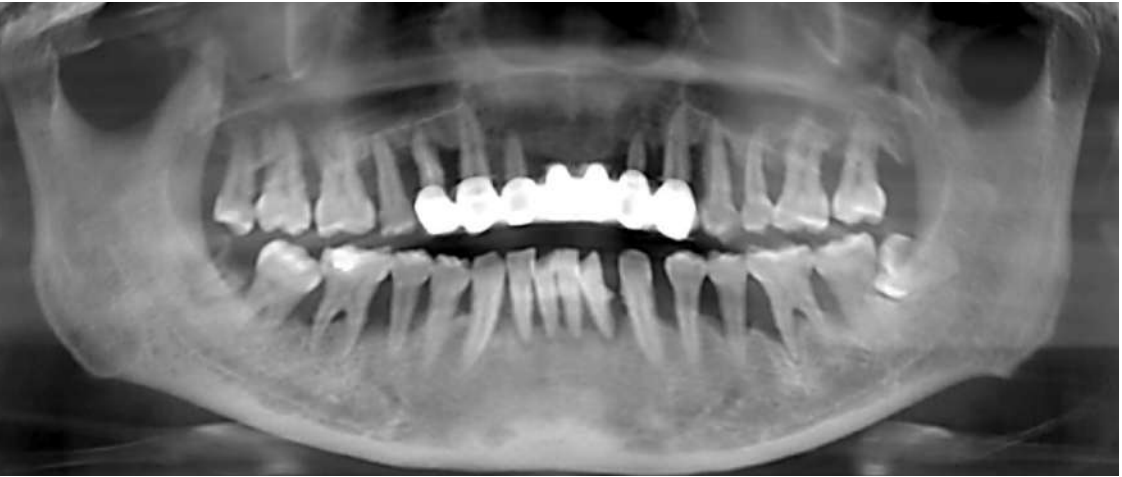BACKGROUND

In end-stage dentition treatment, immediate implant and loading with 4-6 implants can reduce the surgery complexity and patient's terror. Literatures have shown there no significant differences in complication rate, marginal bone resorption and long-term success rate between immediate loading and conventional loading.

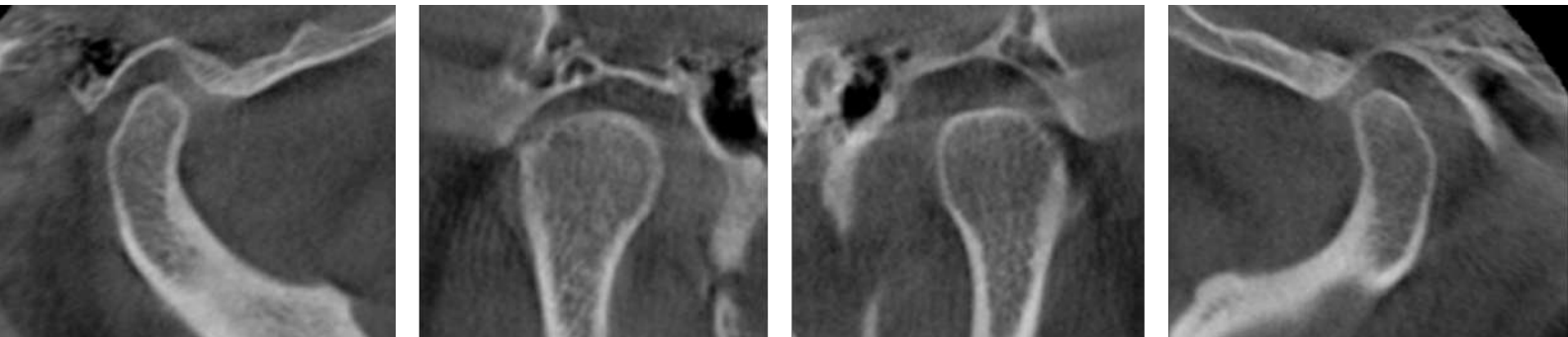
AIM

The presence of severe periodontitis will influence implant survival rate and increase treatment complexity. After removed unreserved teeth, implants were placed to immediately restore the mastication, articulation and aesthetics at same day. This case evaluated its clinical outcome in generalized aggressive periodontitis' mandible with fixed hybrid restoration by 6 years follow-up.

Photo: Initial status, end-stage periodontitis



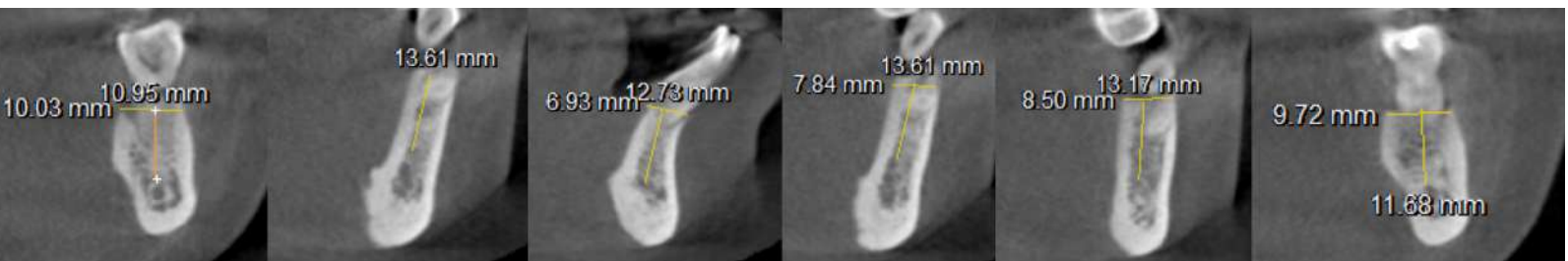
Bilateral condylar cortical bone continuity, no organic lesions



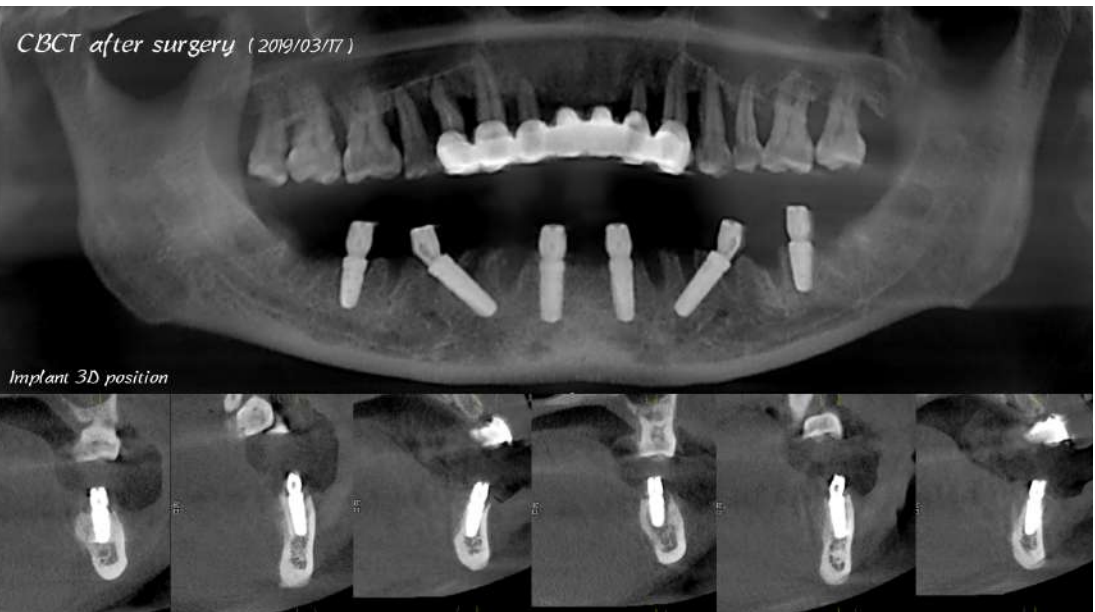
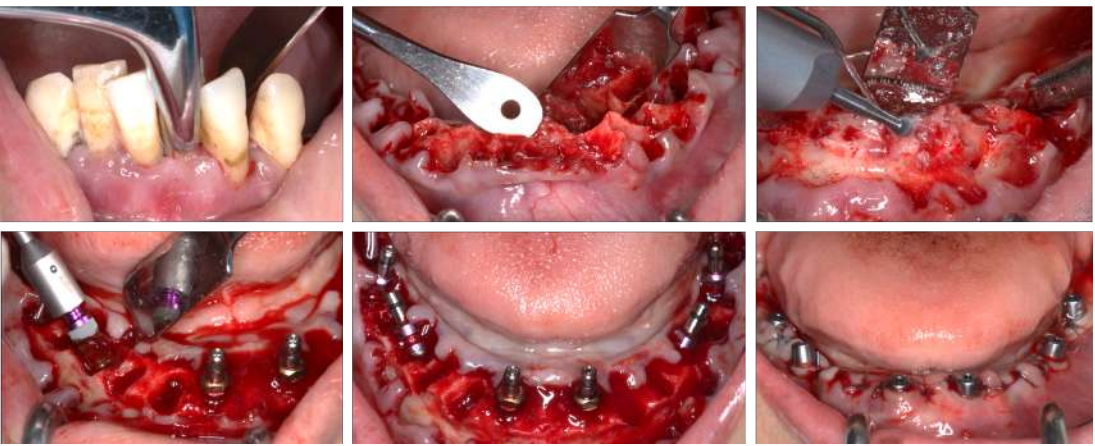
MATERIALS&METHODS

This case report highlights the treatment of immediate implant and loading for end-stage periodontitis (severe extensive stage III). **6 CONELOG implants** were inserted in mandible based on 3-shape digital planning, initial stability all achieved $>35\text{N}\cdot\text{cm}$. The temporary denture was made chairside based on preoperative design data, then installed with **COMFOUR abutment system** at same day to restore chewing articulation function and aesthetics. After 3 months osseointegration, the CAD/CAM titanium bridge and zirconia all-porcelain crown were finally made and installed. Implant System: **CAMLOG Biotech GmbH**

Photo: preoperative plan on CBCT



Surgery & implant 3D position

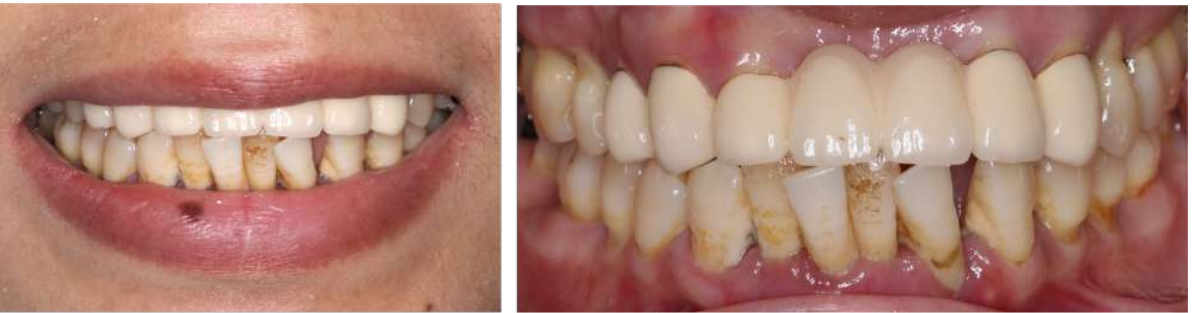

RESULTS

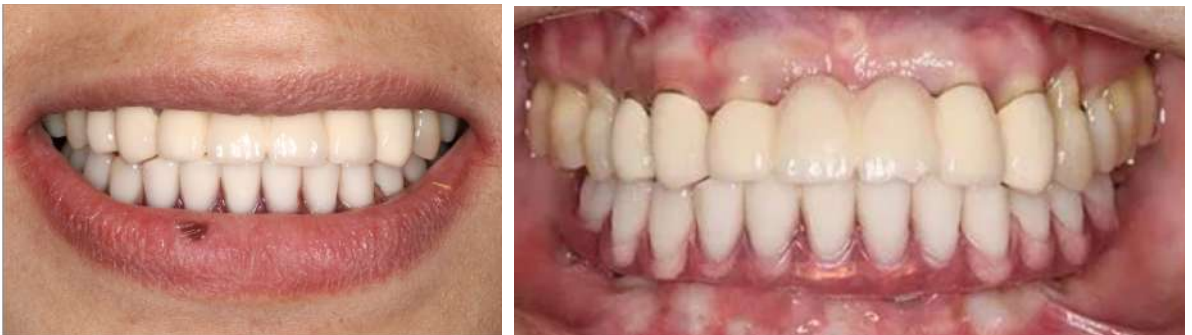After 6 years observation, marginal bone around implant keeps stable. The masticatory efficiency was restored, and the maxillary bone was maximized and retained. Patient's lower 1/3 fullness and masticatory efficiency was greatly restored; implants condition were good.

Photo: after conventional hybrid restoration, contrast with initial status

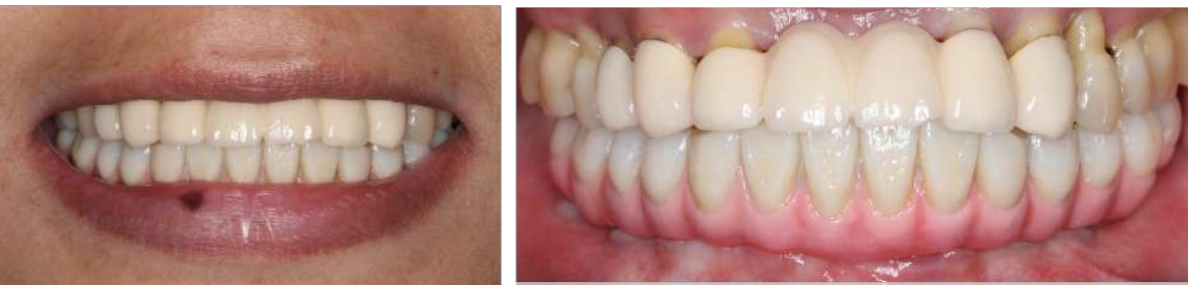A. Initial



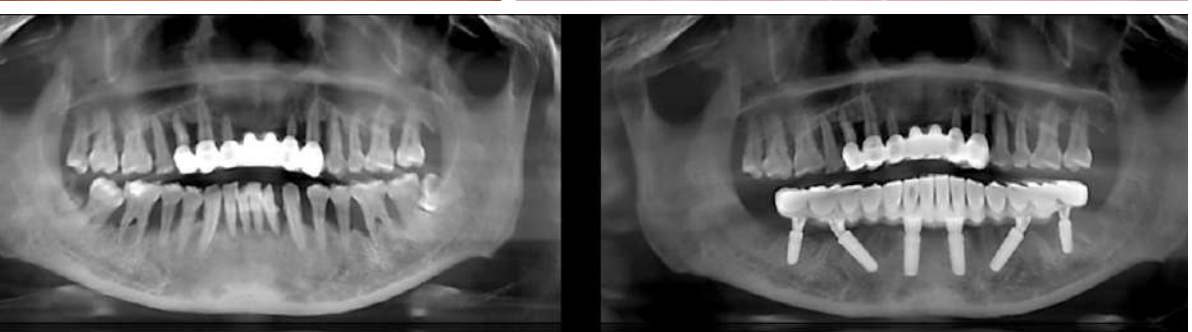
B. Provisional surgery day



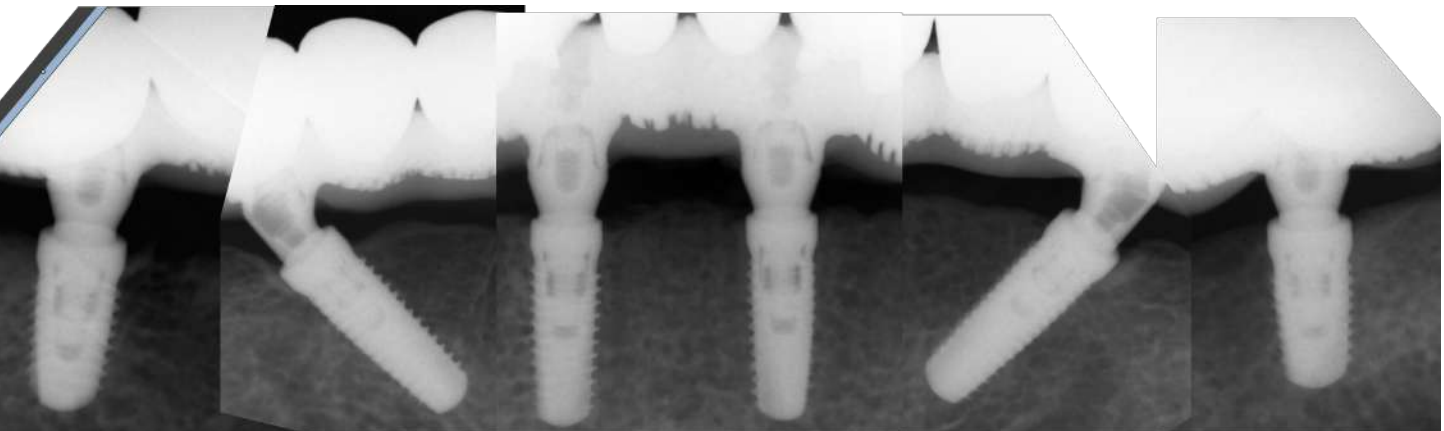
C. Conventional 3 months



D. Xray conventional



E. Xray after 6 years



CONCLUSIONS

Reports have shown there is no significant difference between immediate loading and conventional/delayed loading in post-operative complication/marginal bone resorption/long-term success rate, etc. Immediate loading can shorten treatment period, be minimally invasive, immediately restore aesthetics and function, and greatly improve patients' life quality.

Implant treatment of edentulous needs to consider oral-maxillary function and aesthetics, reasonable and comfortable occlusal relationship for reconstruction. Long-term stability requires regular postoperative maintenance and rational use to reduce the complications.

DISCLOSURE OF INTEREST

The author reports no conflicts of interest. Written informed consent for post of their clinical details and clinical images was obtained from the patient.